

Short communication

Brain structure in diving players on MR imaging studied with voxel-based morphometry

Gaoxia Wei^a, Jing Luo^{a,*}, Youfa Li^b

^a Key Laboratory of Mental Health, Institute of Psychology, Chinese Academy of Sciences, Beijing 100101, China

^b National Key Laboratory of Cognitive Neurosciences and Learning, Beijing Normal University, Beijing 100875, China

Received 1 December 2008; received in revised form 29 December 2008; accepted 31 December 2008

Abstract

We adopted professional diving players as a typical subject pool to explore whether structural brain differences relative to motor skill acquisition exist between highly skilled athletes and non-athletes. Based on the voxel-based morphometric (VBM) technique, structural MRIs of the brains of 12 elite diving players with professional training were analyzed and compared with those of control subjects without any professional physical training. Diving players showed significantly increased gray matter density in the thalamus and left precentral gyrus than control subjects. However, future researches are needed to prove the contribution of preposition and practice. It also suggests that athletes as the subject pool could form a new subject pool to explore plastic change induced by motor skill acquisition. © 2009 National Natural Science Foundation of China and Chinese Academy of Sciences. Published by Elsevier Limited and Science in China Press. All rights reserved.

Keywords: Cortical plasticity; Motor skill acquisition; Voxel-based morphometry; Diving players

1. Introduction

Motor skill acquisition involves several internal processes that improve movement efficiency such as speed, precision, automaticity, and adaptability. These processes are thought to be complex central nervous system phenomena whereby sensory and motor information are organized and integrated [1]. More recently, modern brain imaging techniques, such as positron emission tomography (PET) and magnetic resonance imaging (MRI), have allowed us to identify the anatomical changes induced by motor learning in normal, healthy humans. The studies on cerebral plasticity of taxi drivers, typists, and musicians have greatly increased. Maguire [2] studied London taxi drivers' structural difference compared with controls and found that the posterior hippocampi of taxi drivers were significantly larger than those of control subjects. Another observation on jugglers training also illus-

trated that learning-induced cerebral plasticity is reflected at a structural level [3]. Recently, many studies have focused on musician's brains. These findings revealed structural differences in the brains of adult instrumental musicians compared to those of matched non-musicians and indicated plasticity changes induced by practice in the human brain [4,5]. Schlaug [6] reviewed relevant work on a musician's brain and pointed out that this subject pool became the ideal model to explore the effect of long-term training on the human cerebral cortex.

Just like musicians, athletes are also involved in motor learning and usually practiced motor skills in their earlier childhood. They repeatedly executed almost the same movement everyday once basic skills were mastered. Although a common point is shared in motor learning between musicians and athletes, a remarkable difference exists in the presentation of movement. Instrumentalists are good at operating fine motor units (sequential finger movement), while athletes from most sports are required to recruit gross motor units and muscular tissues based

* Corresponding author. Tel.: +86 10 64836979; fax: +86 10 64851107.
E-mail address: luoj@psych.ac.cn (J. Luo).

on a strict movement sequence. In a sense, it is believed that athletes could be regarded as good subjects of gross motor acquisition. As far as humans are concerned, many daily activities involve gross motor performance such as walking, jumping, throwing, and leaping. These gross motor skills are called fundamental motor skills, which are of great significance to human beings [7]. Nielsen recently [8] pointed out that the plastic adaptive changes that appeared in neuronal circuitries underlying improved performance in relation to skill training and athletes' training were supposed to result in plastic reorganization of the human brain. However, few paid attention to the change in plasticity of the cerebral cortex of athletes induced by motor acquisition. Our interest of this study is whether the cerebral structural differences occurred in sport experts relative to people with no professional motor training. In our study, diving players are selected as the subjects. There are several reasons for this. First, diving players have been engaged early in professional training for a long period without intervals. Secondly, diving is the prototype of gross musculature skill. Thirdly, diving demands good play on strength, coordination and excellent proprioceptive sensation, which exceeded those of simple physical movement or locomotion. Hence, it is predicted that diving players would demonstrate significant structural difference related to motor experience compared to the controls.

2. Methods

2.1. Subjects

In the study, "athlete group" (AG) was defined as full-time motor skill practice with an average daily practice time of at least 5 h. "Non-athletes group" (NG) was defined as the healthy subjects who are not involved in any extensive physical training or professional experience. Twelve elite young divers recruited from the Beijing Diving Team are diving masters and have been experiencing continuous diving training since their childhood (duration ≥ 10.13 years). Twelve controls from the Fengtai Middle School were matched to the diving group for age and gender. There were six males and six females in each group. The age of all subjects ranged from 13 to 17 years, with a mean age of 14.58 (± 1.68) years for AG and 14.92 (± 1.38) years for NG. The difference in mean ages was (95% confidence interval) 0.34 years. All the subjects were right-handed, medically and neurologically stable. No subjects had any lifetime histories of substance dependence. Informed consent from their parents was obtained, and the study was approved by the Institutional Review Board of the Beijing MRI Center for Brain Research and has therefore been performed in accordance with the ethical standards laid down in the 1964 Declaration of Helsinki. Before the scanning, all subjects delivered the volunteers screening forms to the Beijing MRI Center for Brain Research to exclude any subject who had a history of hearing or vision problems, physical injury, a history of sei-

zures, metal implants, and head trauma with loss of consciousness, or pregnancy.

2.2. MR scanning

High-resolution anatomical images of the whole brain were acquired on a 3-tesla Trio System (Siemens, Erlangen, Germany) by using a magnetization-prepared rapid acquisition gradient echo sequence. The following parameters were used for the volumetric acquisition: TR = 2530 ms, TE = 3.37 ms, flip angle = 7 degree, slice thickness = 1.33 mm, FOV = 256 mm, 512×512 -pixel matrix. The voxel size was $0.5 \text{ mm} \times 0.5 \text{ mm} \times 1.33 \text{ mm}$. The scan time for the T1-weighted sequence lasted for 486 s, and the scan was conducted at the end of an fMRI session. During the scanning, each subject reclined in a supine position on the bed of the scanner and was asked to lie still during the imaging time. A foam head holder and padding were placed around the subject's head. In addition, headphones were provided to block background noise. There were no scans with excessive motion artifact.

2.3. VBM protocol

After the acquisition of MR images, DICOM (Digital Imaging and Communications in Medicine) files were transferred to a compatible PC from the MRI Center for Brain Research. Images were then analyzed by the voxel-based morphometric (VBM) technique, a fully automatic technique for computational analysis of differences in local GM volume and concentration. We performed the optimized VBM protocol [9–11] using the SPM 2 package (Institute of Neurology, London, UK; <http://www.fil.ion.ucl.ac.uk>) in MATLAB 6.5 (Math Works, Natick, Mass). In brief, (1) raw images were normalized to the Montreal Neurological Institute (MNI) template, which approximates Talairach space. These normalized images were segmented into gray matter (GM), white matter (WM) and cerebrospinal fluid (CSF) images and then smoothed with an 8-mm Gaussian kernel. All the GM/WM and CSF images were averaged to create separate GM/WM and CSF templates. (2) Raw images were normalized to the MNI template and segmented into GM/WM and CSF images and then normalized to the gray/white matter templates created previously, thus preventing any contribution of non-brain voxels and affording optimal spatial normalization of GM/WM. The optimally normalized images were then segmented into gray and white matter and CSF. (3) Jacobian modulation was applied to GM to restore the original absolute volume altered by the normalization process. (4) Images were smoothed by an isotropic Gaussian kernel with 8-mm FWHM. (5) Differences in local GM and WM volume and density were analyzed across the whole brain. Finally, high-resolution anatomical images (voxel size, 1 mm^3) of the whole brain were acquired by optimized VBM processing.

2.4. Statistical analysis

Cohort analysis was performed with the SPM2 software package. A two-sample t test statistic was applied to density and volume differences between the two groups. Voxel-level data were displayed on the MNI 3D brain template at threshold $p < 0.001$ (uncorrected) with the minimum cluster size of 50 voxels. Points of maximum correlation were converted from MNI to Talairach coordinates with a nonlinear transformation. Additionally, the correlation analysis using athletes' training duration and density of GM was performed and a threshold of $p_{FDR} < 0.05$ (corrected for multiple comparisons across the whole brain) was adopted.

3. Results

3.1. VBM

Statistical comparisons were performed of density between AG and NG (see Table 1). AG showed increased GM density in the thalamus compared to NG ($p < 0.05$ for multiple comparisons; see Fig. 1). Also, greater GM density in the left precentral gyrus (BA 6) was found in athletes when compared with the controls ($p < 0.001$, uncorrected; see Fig. 2). However, a significant decrease in GM density of the bilateral fusiform gyrus (BA 19), left caudate, bilateral parahippocampal gyrus (BA 36), right cerebellum, left lingual gyrus (BA 17), cuneus (BA 18), bilateral middle temporal gyrus (BA 21, BA 37, BA 38) and medial frontal

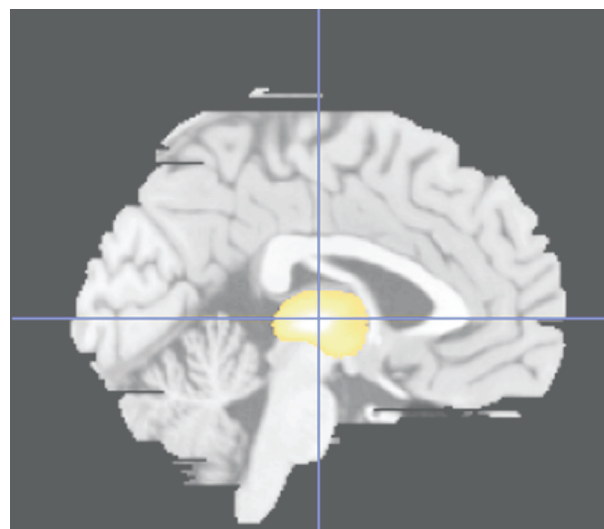


Fig. 1. Areas of greater gray matter density in the thalamus in athletes than in the controls in sagittal view ($x = 0, y = -16, z = -2$).

gyrus (BA 10) in athletes was observed relative to that in controls ($p < 0.001$, uncorrected; see Fig. 2). No significant difference in GM volume was found between these two groups ($p < 0.001$, uncorrected).

3.2. Correlation analysis

No significant correlation was observed between training duration and changes of GM in the thalamus, while

Table 1
Structural difference in GM density between the athlete group and control group.

Contrast	Region	Anatomical region (Brodmann area)	Hemisphere	Talairach coordinates (x, y, z)	Cluster size (voxels)	t	z
A – C	Sub-lobar	Thalamus	L	0 –16 2	4801	6.17	4.65
	Frontal	Precentral gyrus (BA 6)	L	–50 –10 29	483	5.08	4.09
C – A	Temporal	Fusiform gyrus (BA 19)	R	50 –64 –13	3354	6.79	4.93
	Occipital	Middle occipital gyrus (BA 19)	R	62 –69 –14		5.19	4.15
	Posterior cerebellum	Declive	R	57 –75 –16		4.33	3.64
	Temporal	Caudate	L	–31 –33 6	578	6.52	4.81
	Temporal	Sub-gyral	L	–28 –34 –1		4.36	3.66
	Temporal	Fusiform gyrus (BA 19)	L	–49 –67 –13	8844	5.95	4.54
	Posterior cerebellum	Declive	L	–60 –72 –17		5.87	4.51
	Temporal	Middle temporal gyrus (BA 21)	L	–60 –49 –1		5.52	4.33
	Limbic	Uncus (BA 36)	L	–29 –5 –28	1351	5.71	4.43
	Limbic	Parahippocampal gyrus (BA 36)	L	–32 –31 –14		4.69	3.86
	Temporal	Sub-gyral (BA 20)	L	–34 –21 –19		4.35	3.65
	Posterior cerebellum	Uvula	R	32 –66 –24	616	5.41	4.27
	Occipital	Lingual gyrus (BA 17)	L	–11 –88 –1	256	5.33	4.22
	Occipital	Inferior occipital gyrus (BA 17)	L	–18 –90 –6		4.08	3.49
	Occipital	Cuneus (BA 18)	L	–12 –83 29	455	5.30	4.21
	Limbic	Uncus (BA 36)	R	30 –6 –33	215	4.82	3.94
	Limbic	Parahippocampal gyrus (BA 36)	R	42 –20 –16	182	4.80	3.93
	Temporal	Middle temporal gyrus (BA 21)	R	66 –49 8		4.08	3.49
	Temporal	Middle temporal gyrus (BA 38)	L	–39 12 –39	115	4.36	3.66
	Frontal	Medial frontal gyrus (BA 10)	R	4 67 9	120	4.27	3.61

Significant difference in GM density between the athlete group and the control group (A: athlete group; C: control group; A – C: $p < 0.001$, uncorrected; C – A: $p < 0.05$ for multiple comparisons, voxel size > 50 ; L: left hemisphere; R: hemisphere). Coordinates refer to the template space and correspond only approximately to the space of the Talairach atlas.

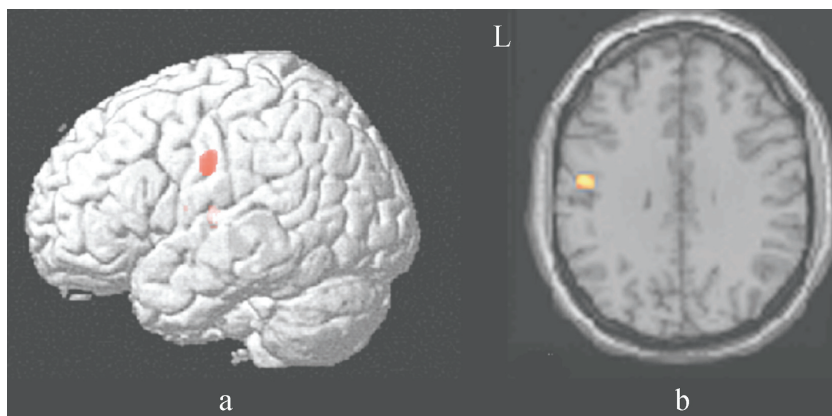


Fig. 2. Statistical parametric maps demonstrating greater GM density of the left precentral gyrus in athletes relative to the controls. Only clusters of voxels consisting of at least 100 voxels are displayed, corresponding to a spatial extent threshold of $p < 0.001$, uncorrected. (a) The clusters were overlaid on the rendered cortex surface of the ch2bet model. (b) The corresponding axial slice (Brodmann area 6; $x = -5$, $y = -10$, $z = 32$). The left side of the picture is the left side of the brain (L).

the GM density of the left prefrontal gyrus varied with the years of training (see Fig. 3). The correlation between GM density and the number of years involving motor practice was greatly significant ($r = 0.91$, $p = 0.0001$).

4. Discussion

Using the voxel-based morphometry, a whole-brain technique that is capable of discovering subtle, regionally specific changes in GM by averaging across subjects, we found greater GM density in the left thalamus and left precentral gyrus in diving players than in the controls, which actually confirmed our hypothesis.

The GM density increase in the left precentral gyrus (BA 6), known for its critical role in motor planning and execution, suggests specific use-dependent plasticity of left frontal lobe structures. This result is supported by some functional studies on plasticity change and reorganization induced by motor learning. Floyer-Lea and his colleagues found that the motor cortex was strongly activated after motor skill training for three weeks [12]. Sequence learning also induced plastic change in the motor cortex [13]. In previous structural analysis with typical subjects, such as

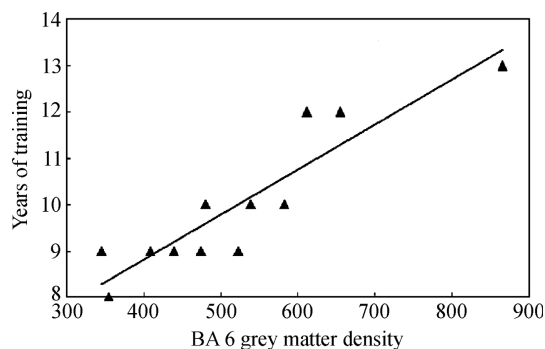


Fig. 3. The correlation of the gray matter density (the cluster size in BA 6) with the years of motor learning.

string players and keyboard players, the motor cortex was also found to be enlarged based on structural magnetic resonance imaging [4,6]. Rosenkranz et al. [14] used TMS to examine how musicians' increased ability to learn new tasks was expressed in neurophysiological parameters of excitability and plasticity in the motor system and inferred that professional musicians showed an increase in number and modifiability of synapses within the motor area caused by long-term musical practice. Previous study on structural change induced by skill training in humans demonstrated that cortical plasticity could be detectable after 5 days [15]. In our study, diving players we recruited had an average training experience of 10 years in a relatively homogeneous environment, which showed a positive correlation with the GM of the precentral gyrus (BA 6). We interpret that this increased GM density in diving players in the motor cortex reflected use-dependent adaptation associated with motor performance for long periods. With a possible interaction between brain development and skill acquisition, motor performance might thus be an environmentally enriching activity, which could promote generation and/or retention of functionally relevant cortical tissue. And thus, we infer that the region of significantly increased GM density identified in VBM analysis might be particularly relevant to long-term motor training. The possible interaction between the plasticity of the motor cortex and skill acquisition has been constantly confirmed by numerous brain imaging studies on motor skill learning [16,17].

Importantly, our finding in greater GM density in the thalamus is of particular interest. Some neurophysiological evidence suggested that the thalamus lesion is associated with motor neglect or disturbances of the body schema [18]. Also, previous clinical studies found reduced GM and fractional anisotropy of the thalamus in movement disorders [19,20]. In our study, we found a specific greater region in the thalamus in the medial dorsal nucleus and pulvinar. This result was also found in animal studies from cats [21] and monkeys [22]. In the literature, it was reported that the change of thalamic neurons could be observed

when injury occurred in the central or peripheral nerve system [23]. No injury, however, was found in AG. In the correlation analysis, we performed years of training and the GM density of the thalamus did not show a significant correlation. It is possible that the density of GM in the thalamus of diving players might be relevant to their genetic predisposition or selection of their certain physical qualities.

Moreover, based on work in animals and humans, motor cortical regions of the frontal lobe and thalamus have been thought to be critical for the acquisition and/or retention of skilled motor behaviors (for reviews, see [24,25]). It is supposed that gray matter density in the precentral gyrus might be closely associated with use-dependent adaptation associated with sports performance, which commenced in childhood and which has continued for around 10 years. In addition, less density in some regions responsible for visual information processing such as the fusiform (BA 19) and parahippocampal gyrus (BA 36) were found in AG relative to NG. Although the exact cause of this difference is still unknown, we performed a paralleled functional MRI study in diving players and controls, which asks the participants to imagine the movements the screen presented before. The results found that the BA 19 and BA 36 were also more greatly activated in athletes than in controls. The findings seem to indicate that there might be a kind of relationship between the increased functional activation and decreased gray matter density in the same regions, which need further investigation.

Our finding might provide a new subject pool for examining whether—and, if so, where—such structural brain plasticity occurs, because athletes continuously practice and acquire a variety of complex motor skills. In various types of sports, different mental or physical abilities might be demanded, some sports (such as basketball and hockey) might need more mental strategies in defense or offense, while others (such as gymnastics and swimming) might rely much on proprioceptive sensation and multisensory feedback [7]. It is supposed to be promising to explore professional athletes' functional and structural plasticity with brain imaging technology. Given that the subjects in our study are teenagers whose brain structure might be influenced by maturation and development, two groups are entirely matched in age in our study. Furthermore, it is well known that diving skills could be mastered and peak performance could be gained in their early youth. Therefore, early youth is regarded as the golden age for Chinese diving players to win the medal, during which the rapid change of brain structure could be clearly detected. Above all, in selecting an athlete model to explore the neural change associated with motor skill, age and sport characteristics should be taken into consideration.

Acknowledgements

This work was supported by the China Postdoctoral Science Foundation (No. 20060390540). We are grateful to

the participating athletes from the Beijing Diving Team and the Beijing Fengtai Middle School for their cooperation. Special thanks are delivered to Shoulong Yuan and Yi Zhou who offered great help in recruiting subjects. Also, we thank the State Key Laboratory of Brain and Cognitive Science for providing technical support. The results of the present study do not constitute endorsement by ACSM.

References

- [1] Lisberger SG. The neural basis for learning of simple motor skills. *Science* 1988;242:728–35.
- [2] Maguire EA, Spiers HJ, Good CD, et al. Navigation expertise and the human hippocampus: a structural brain imaging analysis. *Hippocampus* 2003;13:250–9.
- [3] Draganski B, Gaser C, Busch V, et al. Neuroplasticity: changes in grey matter induced by training. *Nature* 2004;427:311–2.
- [4] Gaser C, Schlaug G. Brain structures differ between musicians and non-musicians. *J Neurosci* 2003;23:9240–5.
- [5] Sluming V, Barrick T, Howard M, et al. Voxel-based morphometry reveals increased gray matter density in Broca's area in male symphony orchestra musicians. *NeuroImage* 2002;17:1613–22.
- [6] Schlaug G. The brain of musicians. A model for functional and structural adaptation. *Ann NY Acad Sci* 2001;930:281–99.
- [7] Magill R. *Motor learning: concepts and application*. New York: McGraw-Hill Higher Education; 2001.
- [8] Nielsen JB, Cohen LG. The Olympic brain. Does corticospinal plasticity play a role in acquisition of skills required for high-performance sports? *J Physiol* 2008;586:65–70.
- [9] Ashburner J, Friston KJ. Voxel-based morphometry—the methods. *NeuroImage* 2000;11:805–21.
- [10] Good CD, Johnsrude I, Ashburner J, et al. Cerebral asymmetry and the effects of sex and handedness on brain structure: a voxel-based morphometric analysis of 465 normal adult human brains. *NeuroImage* 2001;14:685–700.
- [11] Good CD, Johnsrude IS, Ashburner J, et al. A voxel-based morphometric study of ageing in 465 normal adult human brains. *NeuroImage* 2001;14:21–36.
- [12] Floyer-Lea A, Matthews PM. Distinguishable brain activation networks for short- and long-term motor skill learning. *J Neurophysiol* 2005;94:512–8.
- [13] Grafton ST, Hazeltine E, Ivry R. Functional mapping of sequence learning in normal humans. *J Cogn Neurosci* 1995;7:497–510.
- [14] Rosenkranz K, Williamon A, Rothwell JC. Motorcortical excitability and synaptic plasticity is enhanced in professional musicians. *J Neurosci* 2007;27:5200–6.
- [15] May A, Hajak G, Ganssbauer S, et al. Structural brain alterations following 5 days of intervention: dynamic aspects of neuroplasticity. *Cereb Cortex* 2007;17:205–10.
- [16] Karni A, Meyer G, Jezzard P, et al. Functional MRI evidence for adult motor cortex plasticity during motor skill learning. *Nature* 1995;377:155–8.
- [17] Ungerleider LG, Doyon J, Karni A. Imaging brain plasticity during motor skill learning. *Neurobiol Learn Mem* 2002;78:553–64.
- [18] Tang CM. *Neuropsychology*. Beijing: People's Military Medicine Press; 2001.
- [19] Padovani A, Borroni B, Brambati SM, et al. Diffusion tensor imaging and voxel based morphometry study in early progressive supranuclear palsy. *J Neurol Neurosurg Psychiatry* 2006;77:457–63.
- [20] Thivard L, Pradat PF, Lehericy S, et al. Diffusion tensor imaging and voxel based morphometry study in amyotrophic lateral sclerosis: relationships with motor disability. *J Neurol Neurosurg Psychiatry* 2007;78:889–92.
- [21] Moran A, Avendano C, Reinoso-Suarez F. Thalamic afferents to the motor cortex in the cat. A horseradish peroxidase study. *Neurosci Lett* 1982;33:229–33.

- [22] Matelli M, Luppino G. Thalamic input to mesial and superior area 6 in the macaque monkey. *J Comp Neurol* 1996;372:59–87.
- [23] Navarro X, Vivo M, Valero-Cabre A. Neural plasticity after peripheral nerve injury and regeneration. *Prog Neurobiol* 2007;82:163–201.
- [24] Sanes JN, Donoghue JP. Plasticity and primary motor cortex. *Annu Rev Neurosci* 2000;23:393–415.
- [25] Doyon J, Gaudreau D, Laforce Jr R, et al. Role of the striatum, cerebellum, and frontal lobes in the learning of a visuomotor sequence. *Brain Cogn* 1997;34:218–45.