



Cerebral response to patient's own name in the vegetative and minimally conscious states

H.B. Di, MS; S.M. Yu, BSc; X.C. Weng, PhD; S. Laureys, MD, PhD; D. Yu, BSc; J.Q. Li, BSc; P.M. Qin, MS; Y.H. Zhu, PhD; S.Z. Zhang, MS; and Y.Z. Chen, MD

Abstract—Background: A challenge in the management of severely brain-damaged patients with altered states of consciousness is the differential diagnosis between the vegetative state (VS) and the minimally conscious state (MCS), especially for the gray zone separating these clinical entities. **Objective:** To evaluate the differences in brain activation in response to presentation of the patient's own name spoken by a familiar voice (SON-FV) in patients with VS and MCS. **Methods:** By using fMRI, we prospectively studied residual cerebral activation to SON-FV in seven patients with VS and four with MCS. Behavioral evaluation was performed by means of standardized testing up to 3 months post-fMRI. **Results:** Two patients with VS failed to show any significant cerebral activation. Three patients with VS showed SON-FV induced activation within the primary auditory cortex. Finally, two patients with VS and all four patients with MCS not only showed activation in primary auditory cortex but also in hierarchically higher order associative temporal areas. These two patients with VS showing the most widespread activation subsequently showed clinical improvement to MCS observed 3 months after their fMRI scan. **Conclusion:** The cerebral responses to patient's own name spoken by a familiar voice as measured by fMRI might be a useful tool to preclinically distinguish minimally conscious state-like cognitive processing in some patients behaviorally classified as vegetative.

NEUROLOGY 2007;68:895–899

Vegetative state (VS) and minimally conscious state (MCS) are considered different clinical entities, but their bedside differential diagnosis remains challenging. The underlying functional neuroanatomy of VS and MCS is only partly understood.^{1,2} Using neuroimaging, previous studies in patients with VS have shown that simple auditory stimuli activated primary cortices,^{3,4} whereas in patients with MCS, auditory stimuli elicited more widespread activation.⁴ However, some case studies showed that complex auditory stimuli elicited activation beyond the primary cortex even in patients with VS.^{5,6} If these cases of VS were strictly diagnosed, it should be tested in a larger group of patients whether such “high level” cortical activation is the rule rather than

the exception. Furthermore, it will be even more significant in that the separation of patients with VS according to their brain activation to such stimuli might herald further recovery (as was previously shown in two case reports)^{7,8} in this very challenging patient population.

Among emotionally laden auditory stimuli, a person's own name is the most powerful one to gain entry to awareness, as demonstrated in the “cocktail party” phenomenon.⁹ It has been reported that the subject's own name (SON) activated the cerebral cortex more extensively vs nonself referential emotional stimuli in patients with MCS.¹⁰ Furthermore, the SON spoken by a familiar voice (SON-FV), vs an unfamiliar voice, elicited stronger event-related potential (ERP) responses.¹¹ Given these findings, we have chosen to present the SON-FV to maximize our chances of detecting residual brain function in patients with VS and MCS using fMRI.

Additional material related to this article can be found on the *Neurology* Web site. Go to www.neurology.org and scroll down the Table of Contents for the March 20 issue to find the title link for this article.

Editorial, see page 885

From Zhejiang University School of Medicine (H.B.D., Y.H.Z., S.Z.Z., Y.Z.C.) and Hangzhou Teachers College (H.B.D.), Hangzhou, China; Laboratory for Higher Brain Function (X.C.W., P.M.Q.), Institute of Psychology, Chinese Academy of Sciences, Beijing, China; Rehabilitation Center for Brain Damage (S.M.Y., D.Y., J.Q.L.), Wujing Hospital of Hangzhou City, Hangzhou, China; and Cyclotron Research Center and Neurology Department (S.L.), University of Liege; and Neurology Department (S.L.), Sart Tilman University Medical Center, Liege, Belgium.

Supported by the National Science Foundation of China (grant 30425008) and Chinese Ministry of Science and Technology (grant 2003CB515400). S.L. is a research associate supported by the Belgian “Fonds National de la Recherche Scientifique” and the Mind Science Foundation, San Antonio, TX.

Disclosure: The authors report no conflicts of interest.

Received September 18, 2006. Accepted in final form January 9, 2007.

Address correspondence and reprint requests to Dr. Yi Zhang Chen, Zhejiang University School of Medicine, Hangzhou 310006, China; e-mail: yzchen0928@yahoo.com

Table 1 Clinical data of the patients with VS and MCS

Pts.	Sex/age, y	Cause	Time of fMRI (mo after insult)	Lesions on MRI	Deep tendon reflex	Skeletal muscle tone	Babinski sign	Response to noxious stimulation
VS								
1	M/58	Anoxic	4	Right temporal gyrus (diffuse cortical atrophy)	Increased	Rigid	Bilateral	Flexion withdraw
2	M/61	Traumatic	8	Left temporal frontal cortex	Absent	Extensor	Absent	Extension
3	M/29	Anoxic	48	Diffuse cortical atrophy	Increased	Rigid	Bilateral	Flexion
4	M/42	Traumatic	2	Diffuse left hemisphere/right temporal and parietal cortex	Normal	Flaccid	Absent	Extension
5	F/52	Traumatic	2	Right frontal and left temporal cortex	Increased	Rigid	Bilateral	Flexion withdraw
6	M/38	Traumatic	4	Left occipital cortex and bilateral basal ganglia	Decreased	Flaccid	Left	Extension
7	M/21	Traumatic	4	Right temporal, frontal, and parietal cortex	Increased	Rigid	Bilateral	Flexion withdraw
MCS								
1	M/30	Traumatic	2	Right temporal and frontal cortex	Normal	Flaccid	Absent	Flexion withdraw
2	F/24	Traumatic	3	Bilateral frontal subdural hematoma, brainstem	Increased	Flexor	Left	Flexion withdraw
3	M/38	Traumatic	6	Bilateral temporal and frontal cortex	Normal	Rigid	Bilateral	Flexion
4	M/30	Traumatic	26	Left temporal and bilateral frontal cortex	Increased	Rigid	Bilateral	Flexion withdraw

All patients, although suffering bilateral paralysis, had normal breathing and also retained gag reflex.

Pts. = patients; MCS = minimally conscious state; VS = vegetative state.

Methods. *Patients.* This study was prospectively performed in 12 severely brain-damaged patients. None of these patients has been previously reported. Their clinical and structural imaging data are summarized in table 1. All but two patients (VS 1 and 3) were suffering from traumatic brain injury. Patient age ranged from 21 to 61 years, and the time of study ranged from 2 to 48 months post-injury. To make behavioral diagnosis as accurate as possible, special care was taken to evaluate consciousness in each patient using validated behavioral scales. In addition to the Glasgow-Liège Scale (GLS),¹² which adds evaluation of brainstem reflexes to the Glasgow Coma Scale (GCS),¹³ we employed multiple specially devised and standardized behavioral consciousness scales adapted to the VS and MCS population: the Coma Recovery Scale-Revised (CRS-R),¹⁴ the Wessex Head Injury Matrix (WHIM),¹⁵ the Clinical Unawareness Assessment Scale (CUAS),¹⁶ and the Chinese Vegetative State Scale (CVSS)¹⁷ (table 2). Based on extensive and repeated clinical testing, seven patients were classified as patients with VS and five with MCS (one patient with MCS was excluded because her head motion synchronized with the auditory stimuli, making it impossible to disentangle true SON-induced blood oxygenation level-dependent (BOLD) increases from movement-induced artifacts).

To examine the prognostic value of our fMRI study, longitudinal behavioral assessments were repeatedly conducted by means of the CRS-R at the time of scanning, and 1, 2, and 3 months after fMRI acquisition. Informed written consent was obtained from the families of all patients, and the study was approved by the Ethics Committee of Zhejiang University School of Medicine.

Image data acquisition and analysis. We digitally recorded and adapted the SON-FV, which was done by a first-degree family member using GoldWave software (GoldWave Inc.). fMRI scanning was performed using a block design, with six active blocks and seven baseline blocks for each patient. Each active block lasted 12 seconds and seven SON-FVs were presented, whereas each baseline block lasted 18 seconds, in which only the attenuated machine noise was presented. The auditory stimuli were

presented through MRI-compatible noise-attenuated headphones (Resonance Technology, Inc., Los Angeles, CA). Data were collected using a 1.5-T General Electric Sigma Horizon MRI system (GE Medical Systems, Milwaukee, WI). First, 22 axial anatomic images were collected using a T1-weighted spin echo (SE) sequence (repetition time [TR] = 500 msec, echo time [TE] = 9 msec, field of view [FOV] = 240 × 240 mm, slice thickness = 5 mm, skip = 1 mm, matrix = 256 × 256, with the resolution of three dimensions of one voxel: $x = 0.9375$ mm, $y = 0.9375$ mm, $z = 6$ mm). Next, 120 images per slice were acquired using a gradient-echo echo planar imaging (EPI) (TR = 3,000 msec, TE = 60 msec, matrix = 64 × 64, with the resolution of three dimensions of one voxel: $x = 3.75$ mm, $y = 3.75$ mm, $z = 6$ mm). Finally, a fast spoiled gradient recalled (SPGR) sequence (TR = 27 msec, TE = 6 msec, FOV = 240 × 240 mm, matrix = 256 × 256, with the resolution of three dimensions of one voxel: $x = 1.3$ mm, $y = 0.9375$ mm, $z = 0.9375$ mm) was used in a sagittal plane to collect three-dimensional images covering the entire volume of the brain. The imaging procedures and parameters were similar to those of our previously published studies.^{18,19}

AFNI software²⁰ was used for data preprocessing and analysis. After correcting for two- and three-dimensional head motion, the functional images were smoothed using an isotropic gaussian kernel (full width at half maximum = 6 mm). We then used multiple linear regression analysis (using the 3Ddeconvolve program in AFNI) to further correct the head movement artifacts (six estimated motion-induced time series used as noninterest regressors) and to generate activation maps²¹ and identify SON-FV-induced BOLD signal increases.^{18,19} p values were calculated to test the fit between the estimated response and the observed signal for each voxel and corrected for multiple comparisons by combination of individual voxel probability thresholding and minimum cluster size thresholding.²¹ The significantly activated voxels were then superimposed on anatomically defined primary and associative auditory cortices. Accurately identifying these cortical areas in deformed brains may be difficult. Thus, special care was taken to

Table 2 Consciousness scores in the patients with VS and MCS

Patients	GLS score* (EVMR)	WHIM score†	CUAS score‡	CVSS score§
VS				
1	14 (4-1-4-5)	14	4 (1-1-1-1)	7 (0-0-2-0-3-2)
2	12 (4-1-2-5)	3	2 (0-0-1-1)	1 (0-0-1-0-0-0)
3	13 (4-1-3-5)	14	4 (1-1-1-1)	5 (0-0-1-0-3-1)
4	12 (4-1-2-5)	3	1 (0-0-1-0)	3 (0-0-1-0-1-1)
5	14 (4-1-4-5)	14	4.5 (1-1.5-1-1)	5 (0-0-2-0-2-1)
6	12 (4-1-2-5)	14	4.5 (1-1.5-1-1)	3 (0-0-1-0-1-1)
7	14 (4-1-4-5)	3	3.5 (0-1.5-1-1)	5 (0-0-2-1-1-1)
MCS				
1	15 (4-2-4-5)	29	5.5 (1-1.5-2-1)	5 (0-1-2-0-1-1)
2	14 (4-1-4-5)	29	4 (1-1-1-1)	3 (0-0-2-1-0-0)
3	13 (4-1-3-5)	21	3 (0-1-1-1)	2 (0-0-1-0-0-1)
4	15 (4-2-4-5)	35	6.5 (1.5-1.5-2-1.5)	6 (0-1-2-1-2-0)

* GLS (Glasgow-Liège Scale): E (eye response), V (verbal), and M (motor) are scored as in the Glasgow Coma Scale; R (brainstem reflexes): score of 5 indicates preserved fronto-orbicular, oculovestibular, and pupillary reflexes.

† WHIM (Wessex Head Injury Matrix) scores range from 1 (brief eye opening) to 62 (correctly performs posttraumatic amnesia test).

‡ CUAS (Clinical Unawareness Assessment Scale) assesses auditory, visual, and tactile awareness and motor output.

§ CVSS (Chinese Vegetative State Scale) assesses command performance, verbal function, limb and trunk movement, eye movement, swallowing, and emotional reactions.

MCS = minimally conscious state; VS = vegetative state.

segment the bilateral primary and associative auditory cortices of each patient by repeatedly and simultaneously checking the anatomic landmarks^{22,23} in three orthogonal cross-sectional views (axial, coronal, and sagittal) of the individual high-resolution three-dimensional brain images, as described elsewhere.²⁴ Specifically, Heschl gyrus (HG) was defined as the primary auditory cortex (if two HG were present, the anterior gyrus was termed area 41 and the posterior gyrus area 42),²² whereas the planum temporale, the planum polare,²³ and the posterior and lateral extensions of HG were defined as the associative auditory cortices and term as area 21/22.

The presence of gross hydrocephalus and focal pathology in nine of 11 patients caused by traumatic head injury complicated the spatial normalization to a standardized stereotactic template. Hence, instead of normalizing these fMRI images through reference to a healthy brain, we chose to fit the activation maps individually to their respective structural MRI data and performed patient-level rather than group-level analyses.

Results. Patients 1 and 2 with VS failed to show significant cerebral activation at $p < 0.05$ (corrected), although at a lower threshold ($p < 0.005$, uncorrected), both patients showed SON-FV-induced activation within the auditory cortex. While Patients 3, 4, and 5 did show significant activation within these auditory cortices, more widespread activation not only encompassing HG but extending to areas 21 to 22 was observed in Patients 6 and 7 (figure).

All four patients with MCS showed significant activation in primary auditory cortices (HG and areas 41 to 42) extending to higher order associative auditory cortices (including areas 21 to 22). Location and volume of activation clusters are shown in table 3.

Longitudinal behavioral assessments are summarized by means of the CRS-R subscores. Only Patients 6 and 7 with VS showed clinically assessable significant improvement observed 3 months after the fMRI study. Patient 6 could repeatedly follow a command to raise his right arm,

and Patient 7 could repeatedly follow command to raise his arms and head and could track visual stimuli with his right eye, indicating that both patients evolved to an MCS. Meanwhile, the other patients with VS remained vegetative, and the patients with MCS remained minimally conscious at 3-month follow-up (see figures E-1 and E-2 on the *Neurology* Web site at www.neurology.org).

Discussion. Both clinical and functional neuroimaging studies in patients with VS and MCS are methodologically difficult. As mentioned above, the behavioral diagnosis of these clinical entities is theoretically and practically challenging. In the present study, we employed a multitude of adapted standardized test including the recently validated CRS-R scale to minimize the possibility of misdiagnosis of patients with VS.^{25,26} fMRI data acquisition and analysis are even more challenging in patients with VS and MCS.¹ One major source of activation artifacts in noncollaborative brain-damaged patients relates to their head movement in the scanner. Patients with VS and MCS often show reflexive, uncontrolled head, trunk, and limb movements and the MRI scanning noise often tends to increase movement in these patients. To limit head movement during scanning, we used noise-attenuated headphones and homemade head-fixation devices. In the preprocessing procedure of data analysis, head movement was further corrected for by using two- and three-dimensional registration. Finally, using multiple linear regressions, we excluded all the artifactual time points due to major head movement. In one of our patients, however, head motion synchronized

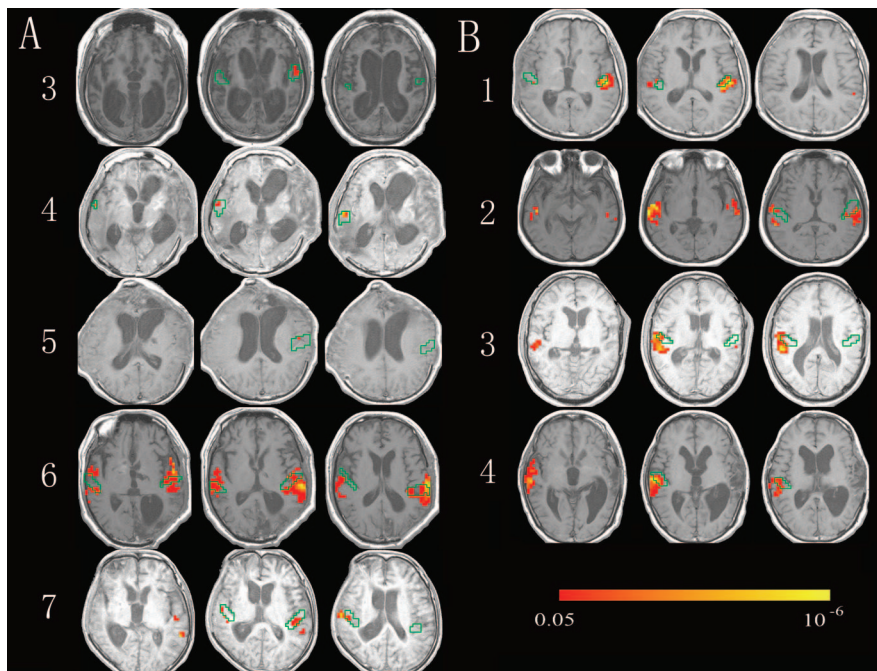


Figure. Areas showing significant ($p < 0.05$, corrected) activation in patients in a vegetative state (VS) (Patients 3, 4, 5, 6, and 7) (A) and patients in a minimally conscious state (MCS) (B). Green contours denote the boundary of the primary auditory areas as defined by anatomic landmarks (see text for details). The patients with VS (Patients 6 and 7), and all four patients with MCS showed activation in associative areas beyond the primary auditory cortex. Left is on the right of the image.

with the auditory stimuli, invalidating further statistical analyses of the data. Hence, this patient was excluded from further analysis. Thus, the reported activation maps seem unlikely to be induced by motion artifacts.

SON-FV elicited significant activation in primary auditory cortex in five of seven patients with VS, whereas the remaining two did not show activation at a significance level of $p < 0.05$ (corrected for multiple comparisons) but did show activation in these

Table 3 The location, volume (mm^3), and voxel number (in parentheses) of activation (significance threshold at $p < 0.05$, corrected for multiple comparisons) elicited by SON-FV in primary and higher order auditory cortices in each patient

Patients	HG and areas 41 and 42		Areas 21 and 22	
	L	R	L	R
VS				
1	0	0	0	0
2	0	0	0	0
3	506 (6)	0	0	0
4	0	422 (5)	0	0
5	84 (1)	0	0	0
6	3,459 (41)	1,688 (20)	9,957 (118)	5,231 (62)
7	675 (8)	422 (5)	591 (7)	759 (9)
MCS				
1	759 (9)	0	2,278 (27)	0
2	675 (8)	0	1,941 (23)	4,050 (48)
3	0	928 (11)	338 (4)	4,894 (58)
4	0	1,181 (14)	0	9,028 (107)

SON-FV = subject's own name spoken by a familiar voice; HG = Heschl gyrus; VS = vegetative state; MCS = minimally conscious state.

regions at a lower threshold ($p < 0.005$, uncorrected). These results confirm previous PET studies on a cohort of patients with VS, in whom simple auditory stimuli elicited group-level activation in primary auditory cortex.^{3,4} Hence, the “classic pattern” of disconnected primary sensory cortex activation in patients with VS could be reproduced at the single-patient level using our fMRI SON-FV paradigm.

Our most surprising finding was the atypical SON-FV-induced activation encompassing not only primary but also hierarchically higher order associative temporal areas in two of seven behaviorally well-documented patients with VS. Such an activation pattern encompassing associative areas was also observed in all four patients with MCS and is in line with previous PET studies of the MCS.^{4,27} The observed activation cluster included the right posterior ending of the superior temporal sulcus, which was previously shown to be involved when hearing one's own name or performing SON-related tasks in healthy controls.²⁸⁻³⁰

More interestingly, only the two patients with VS showing atypical activation spreading to associative areas subsequently recovered to an MCS 3 months after scanning, whereas the other patients remained clinically unchanged. In our opinion, these two patients were already with MCS during fMRI scanning but behavioral signs of consciousness could (even using the best clinical assessments available) only be shown 3 months later. This interpretation is in line with previous reports^{7,8} showing unusual activation of higher order areas (using respectively presentation of familiar faces⁷ and verbal stimuli⁸) followed by clinical recovery some months later. Hence, fMRI seems to offer a higher sensitivity to identify cognitive processing in patients emerging from a VS compared to bedside clinical tools.

Our study emphasizes that functional neuroimaging might subcategorize the clinical entities of VS and MCS and thus may provide an important aid to the differentiation of noncommunicative coma survivors. Although further research is needed to better understand the clinical meaning of the cerebral activations in higher order levels observed in some of our patients with VS, our preliminary data warrant larger scale (multicenter) longitudinal studies including a much larger number of patients to address the prognostic value of the proposed fMRI paradigm.

Acknowledgment

The authors thank Hai Liu for technical assistance.

References

1. Laureys S, Owen AM, Schiff ND. Brain function in coma, vegetative state, and related disorders. *Lancet Neurol* 2004;3:537–546.
2. Schiff ND. Modeling the minimally conscious state: measurements of brain function and therapeutic possibilities. *Prog Brain Res* 2005;150:473–493.
3. Laureys S, Faymonville ME, Degueldre C, et al. Auditory processing in the vegetative state. *Brain* 2000;123:1589–1601.
4. Boly M, Faymonville ME, Peigneux P, et al. Auditory processing in severely brain injured patients: differences between the minimally conscious state and the persistent vegetative state. *Arch Neurol* 2004;61:233–238.
5. De Jong BM, Willemsen ATM, Paas AMJ. Regional cerebral blood flow changes related to affective speech presentation in persistent vegetative state. *Clin Neurol Neurosurg* 1997;99:213–216.
6. Owen AM, Coleman MR, Menon DK, et al. Residual auditory function in persistent vegetative state: a combined PET and fMRI study. *Neuropsychol Rehabil* 2005;15:290–306.
7. Menon DK, Owen AM, Williams EJ, et al. Cortical processing in persistent vegetative state. *Lancet* 1998;352:200.
8. Owen AM, Menon DK, Johnsrude IS, et al. Detecting residual cognitive function in persistent vegetative state. *Neurocase* 2002;8:394–403.
9. Mack A, Pappas Z, Silverman M, Gay R. What we see: inattention and the capture of attention by meaning. *Conscious Cogn* 2002;11:488–506.
10. Laureys S, Perrin F, Faymonville ME, et al. Cerebral processing in the minimally conscious state. *Neurology* 2004;63:916–918.
11. Holeckova I, Fischer C, Giard M-H, Delpuech C, Morlet D. Brain response to a subject's own name uttered by a familiar voice. *Brain Res* 2006;1082:142–152.
12. Born JD, Hans P, Dexters G, et al. [Practical assessment of brain dysfunction in severe head trauma (author's transl)]. *Neurochirurgie* 1982;28:1–7.
13. Teasdale G, Jennett B. Assessment of coma and impaired consciousness. A practical scale. *Lancet* 1974;2:81–84.
14. Giacino JT, Kalmar K, Whyte J. The JFK Coma Recovery Scale—Revised: measurement characteristics and diagnostic utility. *Arch Phys Med Rehabil* 2004;85:2020–2029.
15. Shiel A, Horn S, Wilson BA, et al. The Wessex Head Injury Matrix main scale: a preliminary report on a scale to assess and monitor patients recovery after severe head injury. *Clin Rehabil* 2000;14:408–416.
16. Wade DT, Johnston C. The permanent vegetative state: practical guidance on diagnosis and management. *BMJ* 1999;319:841–844.
17. Meeting summary—expert forum for drawing Chinese diagnostic criterion for VS. *Chin J Emerg Med* 2002;11:241.
18. Xiang H, Lin C, Ma X, et al. Involvement of the cerebellum in semantic discrimination: an fMRI study. *Hum Brain Mapp* 2003;18:208–214.
19. Xiao Z, Lee T, Zhang JX, et al. Thirsty heroin addicts show different fMRI activations when exposed to water-related and drug-related cues. *Drug Alcohol Depend* 2006;83:157–162.
20. Cox RW. AFNI: software for analysis and visualization of functional magnetic resonance neuroimages. *Comput Biomed Res* 1996;29:162–173.
21. Ward BD. Simultaneous inference for fMRI data. Available at: <http://afni.nimh.nih.gov/pub/dist/doc/manual/> Accessed December 25, 2006.
22. Campain R, Minckler J. A note on the gross configurations of the human auditory cortex. *Brain Lang* 1976;3:318–323.
23. Jancke L, Schlaug G, Huang Y, Steinmetz H. Asymmetry of the planum parietale. *Neuroreport* 1994;5:1161–1163.
24. Emmorey K, Allen JS, Bruss J, Schenker N, Damasio H. A morphometric analysis of auditory brain regions in congenitally deaf adults. *Proc Natl Acad Sci USA* 2003;100:10049–10054.
25. Majerus S, Gill-Thwaites H, Andrews K, Laureys S. Behavioral evaluation of consciousness in severe brain damage. *Prog Brain Res* 2005;150:397–413.
26. Andrews K, Murphy L, Munday R, Littlewood C. Misdiagnosis of the vegetative state: retrospective study in a rehabilitation unit. *BMJ* 1996;313:13–16.
27. Schiff ND, Rodriguez-Moreno D, Kamal A, et al. fMRI reveals large-scale network activation in minimally conscious patients. *Neurology* 2005;64:514–523.
28. Perrin F, Maquet P, Peigneux P, et al. Neural mechanisms involved in the detection of our first name: a combined ERPs and PET study. *Neuropsychologia* 2005;43:12–19.
29. Kjaer TW, Nowak M, Lou HC. Reflective self-awareness and conscious states: PET evidence for a common midline parietofrontal core. *Neuroimage* 2002;17:1080–1086.
30. Vogeley K, Bussfeld P, Newen A, et al. Mind reading: neural mechanisms of theory of mind and self-perspective. *Neuroimage* 2001;14:170–181.

UPDATE YOUR PRACTICE IN A WEEKEND AT ANNUAL MEETING

Gain the tools you need to update your practice during the first weekend at the Annual Meeting. Attend the new Practice Colloquium on pay-for-performance and negotiating with payers, the Patient Safety Colloquium, and the BRAINS Colloquium for practice managers. Stay until Monday and attend the Guidelines, Practice, and Advocacy Open House. All are free to registered attendees. Supplement this knowledge with Saturday's full-day practice management course (1FC.001) or half-day course on using guidelines and evidence in daily practice (1PC.002). Visit am.aan.com/other/advocacy.cfm for dates and times.