

## Cortical language activation in aphasia: a functional MRI study

XU Xiao-jun 徐晓俊, ZHANG Min-ming 张敏鸣, SHANG De-sheng 商德胜, WANG Qi-dong 汪启东  
LUO Ben-yan 罗本燕 and WENG Xu-chu 翁旭初

**Keywords:** *aphasia • magnetic resonance imaging, functional • language • human brain mapping*

**Background** Functional neuroimaging has been used in neurolinguistic research on normal subjects and on patients with brain damage. This study was designed to investigate the differences of the neural basis underlying language processing between normal subjects and aphasics.

**Methods** Functional magnetic resonance imaging (fMRI) was used to map the language network in 6 normal subjects and 3 patients with aphasia who were in the stage of recovery from acute stroke. The participants performed a word generation task during multi-slice functional scanning for the measurement of signal change associated with regional neural activity induced by the task.

**Results** In normal subjects, a distributed language network was activated. Activations were present in the frontal, temporal, parietal and occipital regions. In the patient group, however, no activation was detected in the left inferior frontal gyrus whether the patient had a lesion in the left frontal lobe or not. Two patients showed activations in some right hemisphere regions where no activation appeared in normal subjects.

**Conclusions** fMRI with word generation task is feasible for evaluating language function in aphasic patients. Remote effect of focal lesion and functional redistribution or reorganisation can be found in aphasic patients.

*Chin Med J 2004; 117(7):1011-1016*

The studies on aphasia have provided numerous insights into the neural basis of language processing. However, traditional neuropsychological approach to aphasia, which examines the relationship between a given aphasic syndrome and the site of brain damage, is restricted.<sup>1</sup> Research into brain metabolism has revealed that focal brain lesions from stroke can lead to widespread changes in metabolism; that is, the effects of stroke extend to brain regions outside the damaged areas.<sup>2</sup> Furthermore, a damaged brain never freezes in structure and function after a lesion has occurred. Some form of reorganization of the central nervous system occurs after brain damage.<sup>3</sup> Therefore, the anatomical correlation method may not capture the physiological brain changes that accompany a focal brain lesion.

The advent of functional neuroimaging, especially positron emission tomography (PET) and functional magnetic resonance imaging (fMRI), has opened up a new avenue for exploring the neural mechanism underlying the language processing in humans. fMRI is a method to measure blood oxygenation level dependant (BOLD) signal changes that link to regional brain activity in subjects during performance of cognitive, sensory or motor tasks. Because of its

high spatial and temporal resolution and non-invasive nature, fMRI has been widely used in neurolinguistic research on normal subjects, and more recently, on patients with brain damage.<sup>4,5</sup> Some studies have shown that fMRI can reliably detect brain activity during language processing in normal Chinese speakers and in Chinese patients with epilepsy,<sup>6,7</sup> but little has been conducted on Chinese patients with aphasia. In this study, we used the fMRI technique to measure the BOLD signal changes associated with a simple language task in aphasic patients and normal subjects to investigate the differences of neural basis underlying language processing between normal subjects and aphasics.

Departments of Radiology (Xu XJ, Zhang MM, Shang DS and Wang QD) and Neurology (Luo BY), First Affiliated Hospital, School of Medicine, Zhejiang University, Hangzhou 310003, China

Laboratory for Higher Brain Function, Institute of Psychology, Chinese Academy of Sciences, Beijing 100101, China (Weng XC)

Correspondence to: Dr. Zhang Min-ming, Department of Radiology, First Affiliated Hospital, School of Medicine, Zhejiang University, Hangzhou 310003, China (Tel: 86-571-87236521. Fax: 86-571-87236618. Email: zhangminming@163.com; mzhang4@emory.edu)

## METHODS

### Participants

Three aphasic patients were included in this study. They all were right-handed. Patient 1 was a 60 year-old man who came to our hospital following the abrupt onset of severe expressive aphasia. MRI examination the next day showed that there was an acute infarct lesion in the left posterior portion of the inferior and middle frontal gyrus. fMRI experiment was then performed on the 10th day after the onset of the symptoms. At that time he could merely speak a few nonsense words, but his auditory and reading comprehension were normal. Patient 2 was a 34 year-old man who was admitted to our hospital in a coma. CT several hours later showed multiple haemorrhages in the left frontal, parietal and temporal regions. Although the patient recovered consciousness after emergency surgery for hematomas, the symptoms of aphasia appeared. fMRI experiment was performed at the 5th week after admission. By that time the patient somewhat recovered from aphasia; however, his spontaneous speech was still a struggle, and he could not name some common objects accurately, although he could describe some of their features. Patient 3 was a 67 year-old man with progressive aphasia and weakness of the right limbs. MRI on the 10th day after the onset of the symptoms demonstrated a large ischemic infarction in the left temporal region extending to the temporal-parietal junction. fMRI was performed at the 3rd week after the onset of the symptoms. By that time, the patient's aphasia had already recovered to some extent.

Six healthy volunteers aged 24 to 30 years (mean, 26.8 years) were male native Chinese speakers and right handed. None of them reported a history of neurological or psychiatric disorders.

### Language task paradigm

An event related word generation paradigm was adopted to explore the neural network relating to language processing in both normal subjects and patients. The language task consisted of 34 repeated trials. In each trial, a word composed of two Chinese characters was shown to the subjects for 500 ms. The words were the names of common animals or tools. The subjects were instructed to covertly generate, as quickly as possible, a word semantically related to each word they had just viewed. We did not specify or imply to our subjects that some classificatory words should be generated, rather, a semantically associated word of any type was allowed. In order to minimize the anticipation effect from the subjects,<sup>8</sup> the interval between successive

trials was varied (14, 16, and 18 seconds selected randomly). A crosshair fixing point was provided in the interval time and subjects were instructed to see the point and empty their mind.

Before scanning, all the subjects were acquainted with the word generation task using words different from those presented during scanning. Subjects were interviewed about their task performance immediately after the scanning to confirm that they had been attentive and performed the task seriously.

### MRI protocol

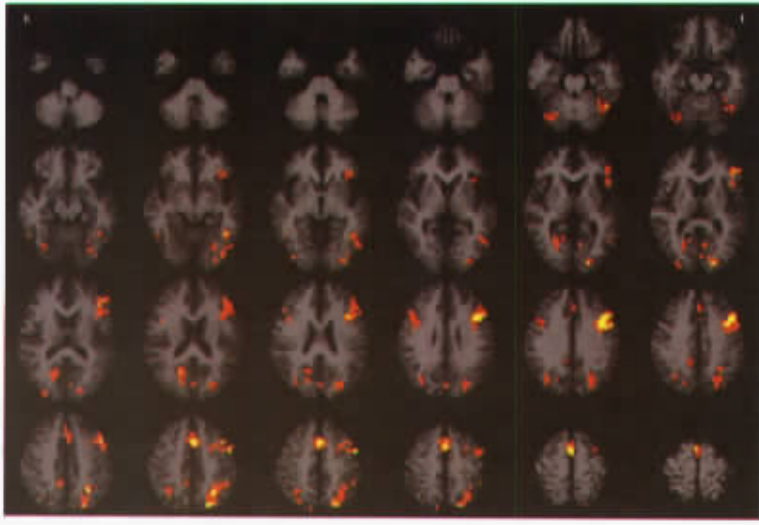
All the scanings were performed on a 1.5 T MR scanner (GE Signa Horizon, Milwaukee). Twenty-two axial T1W reference images, which covered the whole brain, were first acquired with a spin-echo (SE) sequence (TR :TE = 400 ms :9 ms, 256 × 192 pixel matrix, 5 mm slice thickness with 1 mm gap, field of view or FOV = 24 cm × 24 cm). Then, 256 T2\* weighted BOLD images per slice were acquired, in the same location as previous SE sequence, using gradient recalled echo-echo planar imaging (GRE-EPI) sequence (TR :TE = 2000 ms :47 ms, 5 mm slice thickness with 1 mm gap, 64 × 64 pixel matrix, FOV = 24 cm × 24 cm). Finally, 110 continuous sagittal slices were obtained using spoiled gradient recalled (SPGR) sequence (TR :TE = 26 ms :3 ms, 1.5 mm slice thickness, 256 × 160 pixel matrix) for high-resolution 3D anatomic images.

### Image processing and analysis

Image analysis was performed using AFNI software (version 2.51h, Medical College of Wisconsin, USA).<sup>9</sup> The functional data were first registered for motion and phase correction. Then these functional images were co-registered with the 3D anatomic images for accurately locating the activation area. In order to enhance the signal-to-noise ratio, the functional data of each subject was smoothed with an isotropic Gaussian kernel (full width half maximum = 3 mm).

In the normal group, the functional data were transformed to the standard Talairach coordinates and then grouped.<sup>10</sup> A model of the estimated response of the brain was built based on the stimulus function and impulse response functions to the stimulus by using the 3D deconvolution program of AFNI. Then the real observed response data of the brain was compared with the estimated model. An *F* statistic test was applied to test the fitness between the

estimated and observed response of each voxel for the



**Fig. 1.** Activation map during performance of word generation task of normal subjects. Brain activation was observed in the left inferior frontal gyrus, bilateral middle and medial frontal gyrus, left temporal fusiform gyrus, left inferior parietal lobule, bilateral superior parietal lobule and bilateral occipital lobule.

word generation task. Statistical maps then were extracted at an  $F$  value  $>11.71$  ( $P < 1 \times 10^{-8}$ , uncorrected) and superimposed on the high-resolution anatomical images.

In the patient group, the procedure for data processing was identical to that in normal group. Our patients had different lesions, so the functional data were not grouped, but analysed individually. The activation threshold was an  $F$  value  $>9.99$  ( $P < 1 \times 10^{-8}$ , uncorrected).

Time-signal intensity course in region of interest (ROI) was analysed by averaging the 34 trials of the functional data, and then generating a 14-second time course of BOLD signal changes with a temporal resolution of two seconds. The averaged time-signal course represents the cerebral haemodynamic response induced by regional neural activity.

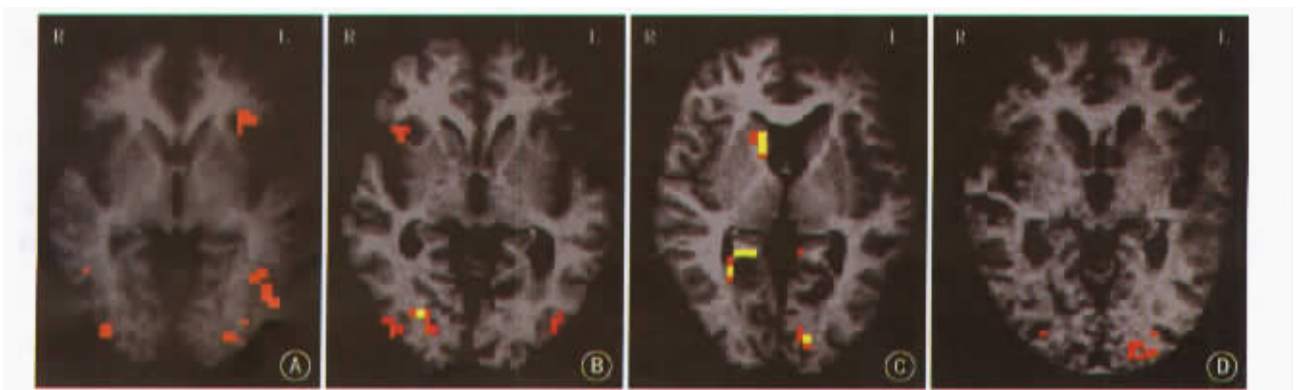
## RESULTS

In normal subjects, word generation tasks activated a

distributed brain areas (Fig. 1), including the left inferior frontal gyrus (BA 44, 45, and 47), bilateral middle and medial frontal gyrus (BA 6, 9, and 46), left temporal fusiform gyrus (BA 37), left inferior parietal lobule (BA 40), bilateral superior parietal lobule (BA 7), and bilateral occipital lobule (BA 17, 18, and 19).

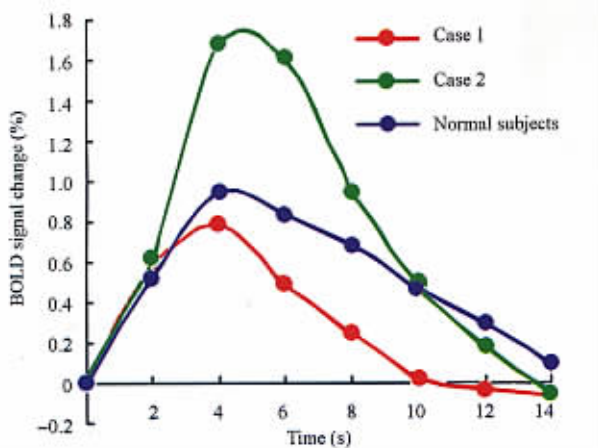
The activation maps of aphasic patients were different from the maps of normal subjects. In patient 1, no activation was found in the left inferior frontal gyrus; however, activation appeared in the homologous area of the right hemisphere. In the other two patients, no activation was found either in the left or in the right inferior frontal gyrus, although in patient 2, activation was showed in the right basal ganglia (Fig. 2).

Based on the activation maps of the normal subjects and patients, we selected the left inferior frontal gyrus of the normal subjects, the right inferior frontal gyrus of patient 1, and the right basal ganglia



**Fig. 2.** Different brain activation patterns induced by the word generation task in normal subjects and patients. **A:** the activation in the left inferior frontal gyrus of normal subjects; **B:** the activation in the right inferior frontal gyrus of case 1; **C:** the activation in the right basal ganglia of case 2; and **D:** no activation was observed in bilateral inferior frontal gyrus of case 3.

of patient 2 as the ROIs. Fig. 3 illustrates the averaged time course of the BOLD signal changes extracted from these ROIs. Despite marked variation in the shape of the curves, the time-signal intensity courses had two important common points; they all reached a maximum in about 4 to 5 seconds and returned to the baseline in about 14 seconds after the word had been shown.



**Fig. 3.** Averaged time courses of the BOLD signal changes in the left frontal gyrus of normal subjects, the right frontal gyrus of patient 1, and the right basal ganglia of patient 2.

## DISCUSSION

Functional brain imaging methodologies are used to investigate the working brain at a system level during psychological tasks. In recent years, there has been a substantial increase in using them to explore the relationship between brain mechanisms and language processing. Since Petersen et al<sup>11</sup> used verb generation task in their ground-breaking functional brain imaging experiment in 1988, the verb generation task has become a common paradigm adopted to understand how the human brain deals with language. The word generation task which was developed by Tan LH et al<sup>12</sup> is similar to the verb generation task, but our subjects were not restricted to generating a verb. In our study, a large-scale brain network, including the Broca's area (BA 44 and 45) and Wernicke's area (BA 40), were activated by word generation task in normal subjects. Comparing the activation patterns of our study with the results of other word/verb generation studies using Chinese,<sup>12</sup> Japanese<sup>13</sup> and English,<sup>12,14,15</sup> we found that the activation in the left inferior frontal area was consistent no matter what kind of language was used in the study. Many studies have shown that the left inferior frontal area is engaged in some aspects of semantic and/or phonological analysis during

language processing.<sup>16,17</sup> Although the exact role of the left inferior frontal area in language processing remains unclear, it seems reasonable to conclude that it is crucial for word/verb generation tasks.

In addition to the reliable localization of the language functional areas in normal subjects, the present study further demonstrates that an fMRI activation study with word generation task can also pinpoint the language relevant regions in aphasic patients. As we had expected, the activation patterns of patients were different from that of normal subjects. There were two noticeable findings in our study.

Firstly, none of the three patients showed activation in the left inferior frontal gyrus, an area ubiquitous to word generation task in normal subjects. Although patient 1 and 2 had lesions in the left frontal lobe, which may account for the reason why no activation was found in the left inferior frontal area, patient 3 had a lesion in the left temporal lobe instead of in the left frontal lobe. We argue that this could be explained by remote effect that refers to regionally functional change at sites that are remote from, but functionally connected to, damaged regions. In theory, a normal neural response in any brain region is driven and modulated by, or interacts reciprocally with, many other regions. The remote effect might be that a viable cortical region expresses aberrant neuronal response when it has an interaction with a damaged region.<sup>18</sup> According to the Wernicke-Lichtheim-Geschwind model of language, Broca's area, localized to the left inferior frontal lobe, and Wernicke's area, localized to the posterior part of the left superior temporal gyrus, are interconnected through the arcuate fasciculus.<sup>19</sup> A functional neuroimaging study also shows that patients with a focal brain lesion in Broca's area have abnormal activation responses in the left posterior inferior temporal region.<sup>18</sup> Thus, we speculate that the lesion in the left temporal lobe of the third patient might interrupt the connection between the left frontal and temporal region, thereby resulting in functional changes in the left frontal lobe.

Secondly, activations in some regions of the right hemisphere were found in two patients, which were not found in normal subjects. It is now apparent that the processing of language requires a large network of interacting brain areas; focal brain damage and subsequent recovery constitute a change to the large-scale network.<sup>19,20</sup> The undamaged network components are reorganized, or new components such as contralateral homology are recruited, to support the language function. The aphasic patient's

language performance depends on the capacity of the language network spared by the injury and the recruitment of new areas to cope with the defect. For example, when Broca's area was entirely or partially destroyed, the activation in the inferior frontal gyrus changed from left to right hemispheric region, and the patient's performance of language tasks was dependant on the participation of the homologous right hemispheric region.<sup>20-22</sup> In our study, patients had the fMRI experiments ten days to five weeks after the onset of their symptoms. All the patients showed some degree of spontaneous recovery from their aphasia during the days or weeks following the initial insult. At that time, we found some right hemispheric activation. The time course of the BOLD signal changes from those regions reached their maximum after 4 to 5 seconds and returned to the baseline 14 seconds after the stimulus' onset. Based on the knowledge of basic characteristics of the homodynamic response of event-related fMRI,<sup>23</sup> we believe that the activations observed at these regions are induced by our language task. Therefore, we consider that the active areas in the right hemisphere might be functional redistribution or reorganization from left hemisphere to the right hemisphere during the recovery of aphasic patients. Our finding, which is in line with the results of other neuroimage studies concerning the recovery from aphasia after left hemisphere stroke,<sup>20-22</sup> may indicate that the nondominant language hemisphere plays a role in recovery from aphasia.

Although the mechanisms underlying recovery of language function after acute brain injury are controversial, there is no doubt that in most patients language improvement is associated with modifications at the neural level.<sup>24</sup> Converging evidence from functional neuroimaging studies, clinical studies, and other data suggest that the primary candidates include undamaged portions of the language network in the left hemisphere and/or homologous right hemisphere areas.<sup>25</sup> The contribution of intact and newly recruited components to language can only be analysed by functional methods such as functional neuroimaging.<sup>24</sup> Our findings demonstrate that an fMRI activation study with word generation task can map the language network in Chinese aphasic patients as well as in normal subjects. The experiment can be finished within 30 minutes, and is easy for patients to deal with. Moreover, the phenomena can be found of remote effect of local lesion and language function redistribution or reorganization in aphasic patients. In order to understand the neural basis of language function recovery from aphasia completely, further

studies should include a longitudinal investigation, which precisely monitors any changes in the organization of the neural network involved in language processing during the course of spontaneous or invention-based recovery, and a known connection between the change of activation pattern and language performance.

The major limitation of this study is the use of covert verbal responses, which prevents us from monitoring the performance of the subjects during scanning directly. The behavioural data collected immediately after scanning may be considered as an approximation to actual performance. It must be noted that since all subjects had been trained with comparable word task before scanning in this study, their level of behavioural performance was well known.

In conclusion, fMRI study with word generation task is suitable for evaluating language function in aphasic patients. Remote effect of focal lesion and functional redistribution or reorganization can be found in aphasic patients.

#### REFERENCES

1. Demonet JF, Thierry G. Language and brain; what is up? What is coming up? *J Clin Exp Neuropsychol* 2001;23:49-73.
2. Ohno T, Bando M, Nagura H, et al. Apraxic agraphia due to thalamic infarction. *Neurology* 2000; 54: 2336-2339.
3. Chen R, Cohen LG, Hallett M. Nervous system reorganization following injury. *Neuroscience* 2002;111: 761-773.
4. Small SL, Burton MW. Functional magnetic resonance imaging studies of language. *Curr Neurol Neurosci Rep* 2002;2:505-510.
5. Pizzamiglio L, Galati G, Committeri G. The contribution of functional neuroimaging to recovery after brain damage: a review. *Cortex* 2001;37:11-31.
6. Ma L, Tang Y, Wang Y, et al. Mapping associated with Chinese word processing using functional magnetic resonance imaging. *Chin Med J* 2003;116:176-180.
7. Gao X, Jang C, Lu C, et al. Determination of the dominant language hemisphere by functional MRI in patients with temporal lobe epilepsy. *Chin Med J* 2001; 114:711-713.
8. Petersen SE, Mier HV, Fiez JA, et al. The effect of practice on the functional anatomy of task performance. *Proc Natl Acad Sci USA* 1998;95:853-860.
9. Cox RW. AFNI; software for visualization and analysis of functional magnetic resonance neuroimages. *Comput Biomed Res* 1996;29:162-173.
10. Talairach J, Tournoux P. Co-planar stereotactic atlas of the human brain. New York: Theime Medical Publishers; 1988:37-84.
11. Petersen SE, Fox PT, Posner MI, et al. Positron emission tomographic studies of the cortical anatomy of

- single-word processing. *Nature* 1988;331:585-589.
12. Tan LH, Spinks JA, Gao JH, et al. Brain activation in the processing of Chinese characters and words; a functional MRI study. *Hum Brain Mapp* 2000;10:16-27.
  13. Tatsumi IF, Fushimi T, Sadato N, et al. Verb generation in Japanese; a multicenter PET activation study. *Neuroimage* 1999;9:154-164.
  14. McCarthy G, Blamire AM, Rothman DL, et al. Echo-planar magnetic resonance imaging studies of frontal cortex activation during word generation in human. *Proc Natl Acad Sci USA* 1993;90:4952-4956.
  15. Xiong JH, Rao S, Gao JH, et al. Evaluation of hemispheric dominance for language using functional MRI: a comparison with positron emission tomography. *Hum Brain Mapp* 1998;6:42-58.
  16. Gabrieli JD, Poldrack RA, Desmond JE. The role of left prefrontal cortex in language and memory. *Proc Natl Acad Sci USA* 1998;95:906-913.
  17. Bookheimer S. Functional MRI of language: new approaches to understanding the cortical organization of semantic processing. *Ann Rev Neurosci* 2002; 25: 151-188.
  18. Price CJ, Warburton EA, Moore CJ, et al. Dynamic diaschisis: anatomically remote and context-sensitive human brain lesions. *J Cogn Neurosci* 2001;13:419-429.
  19. Dronkers NF, Pinker S, Damasio A. Language and aphasia. In: Kandel ER, Schwartz JH, Jessell TM, eds. *Principles of neural science*. 4th edition. New York: McGraw-Hill; 2000;1169-1187.
  20. Thulborn KR, Carpenter PA, Just MA. Plasticity of language-related brain function during recovery from stroke. *Stroke* 1999;30:749-754.
  21. Perani D, Cappa SF, Tettamanti M, et al. An fMRI study in word retrieval in aphasia. *Brain Lang* 2003;85: 357-368.
  22. Ohyama M, Senda M, Kitamura S, et al. Role of the nondominant hemisphere and undamaged area during word repetition in poststroke aphasics; a PET activation study. *Stroke* 1996;27:897-903.
  23. Buckner RL. Event-related fMRI and the hemodynamic response. *Hum Brain Mapp* 1998;6:373-377.
  24. Cappa SF. Recovery from aphasia: why and how? *Brian Lang* 2000;71:39-41.
  25. Thompson CK. The neurobiology of language recovery in aphasia. *Brian Lang* 2000;71:245-248.

(Received September 4, 2003)

本文编辑: 顾佳