

## Mapping cortical areas associated with Chinese word processing using functional magnetic resonance imaging

MA Lin 马林, TANG Yiyuan 唐一源, WANG Yan 王岩, LI Dejun 李德军, WENG Xuchu 翁旭初  
ZHANG Wutian 张武田, ZHUANG Jiancheng 庄建程 and HU Xiaoping 胡小平

**Keywords :** *language tests · semantic differentiation · magnetic resonance imaging · cerebral dominance*

**Objectives** To identify the cortical areas engaged during Chinese word processing using functional magnetic resonance imaging (fMRI) and to examine the reliability and reproducibility of fMRI for localization of functional areas in the human brain.

**Methods** fMRI data were collected on 8 young, right-handed, native Chinese speakers during performance of Chinese synonym and homophone judgment tasks on two different clinical MRI systems (1.5 T GE Signa Horizon and 1.5 T Siemens Vision). A cross correlation analysis was used to statistically generate the activation map.

**Results** Broca's area, Wernicke's area, bilateral extrastriate, and ventral temporal cortex were significantly activated during both the synonym and homophone activities. There was essentially no difference between results acquired on two different MRI systems.

**Conclusions** fMRI can be used for localizing cortical areas critical to Chinese language processing in the human brain. The results are reliable and well reproducible across different clinical MRI systems.

*Chin Med J 2003 ; 116( 2 ):176-180*

Language is an important function for human beings. In various cerebral lesions, the verification of the hemispheric dominance of language should be performed before treatment so as to avoid injury to linguistic function. Over the past 4 decades, the Wada test has been a primary clinical protocol for assessment of hemispheric dominance of language function.<sup>1</sup> However, this test is highly invasive and very distressing for patients, as they must receive an intracarotid administration of sodium amytal.<sup>1,2</sup> The past few years have seen a great deal of progress in functional brain imaging techniques.<sup>3</sup> Of particular interest is to precisely localize human brain functions, including language processing, using clinical conventional magnetic resonance imaging (MRI) systems. As a result, functional magnetic resonance imaging (fMRI) has been proposed as a non-invasive alternative to the Wada test.<sup>4,5</sup>

The present study was designed to ascertain whether blood oxygenation level dependent (BOLD) fMRI is feasible for precisely localizing cortical areas associated with Chinese language processing. To further examine reproducibility and enhance reliability of this kind of study, we conducted the same experiment on two different clinical MRI systems in separate institutions. We employed synonym and homophone

judgment tasks for assessment, as these tasks have been well studied in behavior and are easy to perform. In addition, these tasks require use of two basic components of word reading: semantic and phonological processes, and are thus have theoretical implications.

### METHODS

#### Subjects

The participants were 8 healthy, right-handed, native

Department of Radiology, PLA General Hospital, Beijing 100853, China (Ma L and Li DJ)

Laboratory for Higher Brain Function, Institute of Psychology, the Chinese Academy of Sciences, Beijing 100101, China (Ma L, Tang YY, Wang Y, Li DJ, Weng XC, Zhang WT and Zhuang JC)

Laboratory for Brain and Mind, Dalian University of Technology, Dalian 116024, China (Tang YY)

Department of Radiology, University of Minnesota, Minneapolis, MN 55455, USA (Zhuang JC and Hu XP)

Correspondence to: Prof. Weng Xuchu, Laboratory for Higher Brain Function, Institute of Psychology, the Chinese Academy of Sciences, Beijing 100101, China (Tel: 86-10-64854476. Fax: 86-10-64872070. Email: wengxc@psych.ac.cn)

This study was supported by grants from the Chinese Ministry of Science and Technology (G1999054006), National Institutes of Health, USA (5 RO1 MH55346).

Chinese speakers. Four were males and 4 were females, with ages ranging from 23 to 36 years old. They were either recruited from the campus of the Graduate School of the Chinese Academy of Sciences in Beijing or from the program of China at the University of Minnesota in USA. Informed consent approved by the institutional review board was obtained from each subject.

### Imaging procedure

MR imaging was performed on a 1.5 T Siemens MR scanner (Vision) in Minneapolis, MN, USA or on a 1.5 T GE MR scanner (Signa Horizon) in Beijing, China. Experiments were conducted on Siemens scanner in 4 subjects and on a GE scanner in 5 subjects (one of the subjects participated in the same experiment twice, first on the Siemens and again on the GE), therefore nine experiments were conducted in this study.

On the Siemens scanner, the slice thickness was 7 mm without gaps for both anatomical and functional scans. Two-dimensional anatomical images were first acquired using a FLASH (fast low angle shot) pulse sequence with a matrix of  $256 \times 256$ . For functional imaging, BOLD imaging using a gradient echo EPI (echo planar imaging) sequence (TR = 2000 ms, TE = 55 ms, flip angle =  $90^\circ$ ) was employed. One hundred sixty-seven images per slice were acquired over the same 12 slices as used in the anatomical scanning. At the end of each study, a 3-dimensional FLASH pulse sequence was used to obtain the 3-dimensional anatomical data.

On the GE scanner, 10 to 14 conventional axial anatomical T1-weighted images were first collected with a spin echo (SE) pulse sequence (TR = 500 ms, TE = 14 ms, slice thickness = 6 mm, gap = 1 mm, matrix =  $256 \times 192$ ). One hundred twenty-four functional images per slice were then acquired in the same slices used in the anatomical scanning, using a single shot gradient-echo EPI pulse sequence (TR = 2000 ms, TE = 40 ms, flip angle =  $90^\circ$ , slice thickness = 6 mm, gap = 1 mm, matrix =  $64 \times 64$ ). Finally, 64 continuous sagittal slices covering the entire brain were acquired with a fast spoiled gradient echo (FSPGR) pulse sequence for subsequent 3-dimensional reconstruction and spatial normalization.

### Linguistic tasks

There were 2 linguistic tasks, in which the subjects were instructed to press a button if the presented pairs of Chinese words had similar meanings in the synonym judgment task or had same pronunciation in the homophone judgment task. High frequency, neutral, and single-character words were used in the test. Words with emotional meaning were excluded. Passively viewing a crosshair in the center of the screen served as the baseline control task.

An LCD projector was used to project the PC-generated stimuli onto a screen that was visible from inside the MR scanner. A series of functional MR images were collected while 8 to 12 blocks of linguistic and baseline control tasks were alternated as follows (counter-balanced across subjects): baseline-homophone-baseline-synonym... , or baseline-synonym-baseline-homophone... Each block lasted for 20 s or 40 s. For each block of linguistic tasks, 10 pairs of Chinese words were presented.

### Data analysis

Data analysis was performed using AFNI software<sup>6</sup> on a SUN SPARC workstation. The functional images were spatially registered so as to check and correct for motion artifacts. They were then co-registered to the 3D structural images and normalized according to the standard coordinates defined by Talairach and Tournoux<sup>7</sup> atlas. To enhance signal to noise ratio, the images were re-sampled at  $3 \text{ mm} \times 3 \text{ mm} \times 3 \text{ mm}$  and smoothed with an isotropic Gaussian kernel (FWHM = 5 mm).<sup>6</sup> The runs for time series data were analyzed by correlating the time course for each voxel with an ideal trapezoidal reference waveform corresponding to the timing of linguistic tasks (3 modes including synonym and homophone judgment, synonym judgment, and homophone judgment, respectively). Voxels meeting or exceeding a correlation coefficient of 0.40 ( $r = 0.40$ ,  $P < 0.00001$ ) were considered as reliably associated with the linguistic tasks. The activated voxels were then superimposed on the anatomical images to produce the activation maps.

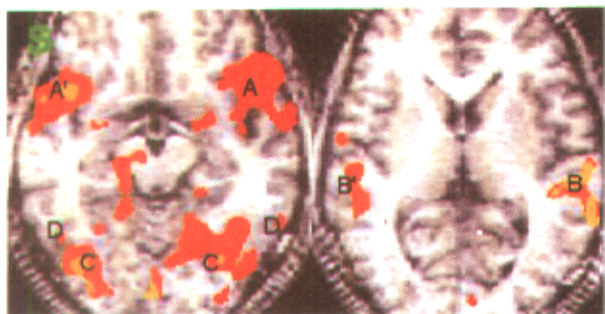
Student's *t* test was used to examine the possible differences between activation during performance of homophone and synonym judgment tasks. The data acquired from the 2 different scanners were not further compared because each of them was statistically analyzed using correlation analysis with the same ideal reference waveform and same correlation coefficient.

## RESULTS

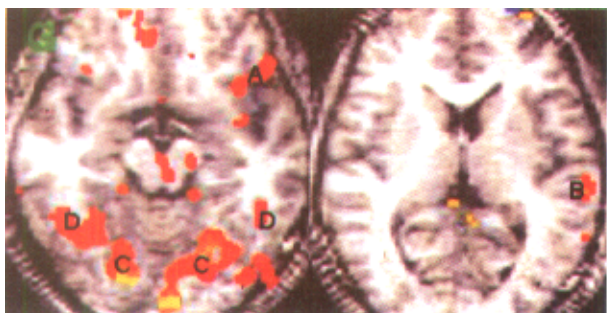
For all 8 subjects, the activation areas of the cerebral cortex during either synonym or homophone judgment tasks were mainly located on the left hemisphere, including Broca's area and Wernicke's area. Activation was also observed in the bilateral supplementary motor area (SMA), extrastriate visual areas, and ventral temporal cortex. There was no significant difference between activation patterns based on data collected on the Siemens scanner or the GE scanner.

One of the subjects was tested on both scanners while he was performing the same linguistic tasks. Both GE and Siemens data revealed activation of an extensive network, including

Broca's area , Wernicke's area , bilateral extrastriate visual cortex , and ventral temporal cortex . However , more activated voxels in Broca's and Wernicke's areas were found in the Siemens data ( Fig. 1 ) than in the GE data ( Fig. 2 ). Furthermore , 2 additional activation areas were observed in the Siemens data , which were located in the inferior frontal cortex and superior temporal gyrus on the right hemisphere , mirroring the traditional Broca's and Wernicke's areas ( Fig. 1 ).



**Fig. 1.** Activation maps based on Siemens data during performance of homophone and synonym tasks. **A** : Broca's area ; **B** : Wernicke's area ; **C** : bilateral extrastriate visual cortex ; **D** : ventral temporal cortex. Additional activation areas located in the inferior frontal cortex (**A'**) and superior temporal gyrus (**B'**) on the right hemisphere are demonstrated , mirroring the traditional Broca's area (**A**) and Wernicke's area (**B**).

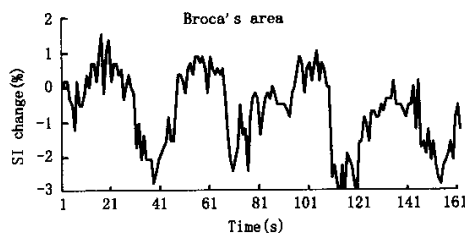


**Fig. 2.** Same subject as in **Fig. 1**. Activation maps based on GE data during performance of homophone and synonym tasks. **A** : Broca's area ; **B** : Wernicke's area ; **C** : bilateral extrastriate visual cortex ; **D** : ventral temporal cortex. Activation areas markedly decreased compared with that acquired on Siemens scanner , indicating the learning effect.

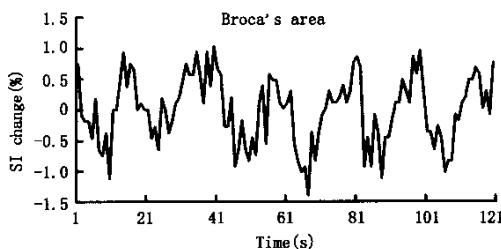
With data collected on the two scanners , we also compared the time course of signal intensity changes in 4 primary activated areas. No substantial differences were detected in the time courses of Broca's area ( Figs. 3 and 4 ) , Wernicke's area , left extrastriate visual areas , and left ventral temporal cortex between Siemens scanner and GE scanner .

To investigate the possible differences between activation

during performance of homophone and synonym tasks , we generated activation maps by use of different references. One corresponded to the homophone judgment task and the other to the synonym judgment task. No essential difference was found in the 2 activation maps. Student's *t* test failed to show significant differences between activation during performance of synonym and homophone judgment tasks (  $t = 0.35$  ,  $P > 0.05$  ). The time courses of 4 areas associated with the tasks again indicated that response to the synonym judgment task was virtually identical to that of homophone judgment task .



**Fig. 3.** Time-signal intensity course in Broca's area on the left hemisphere as revealed by the Siemens data. There were 4 task-control circles in the pulse sequence , alternating in as follows : baseline—homophone ( or synonym )—baseline—synonym ( or homophone )... The curve represents the increase and decrease of the signal intensity in the corresponding activation areas as the task-control stimulation is given to the subject. The transverse axis represents time ( s ) , and the longitudinal axis represents signal intensity ( SI ) change ( % ) .



**Fig. 4.** Time-signal intensity course in Broca's area on the left hemisphere as revealed by the GE data. There were 6 task-control circles in the pulse sequence , alternating as follows : baseline—homophone ( or synonym )—baseline—synonym ( or homophone ) . The curve represents the increase and decrease of the signal intensity in the corresponding activation area as the task-control stimulation is given to the subject. The transverse axis represents time ( s ) , and the longitudinal axis represents signal intensity ( SI ) change ( % ) .

## DISCUSSION

fMRI is an imaging method of choice for the in vivo demonstration of human brain activity. The high spatial and

temporal resolution and non-invasive nature of fMRI have made it widely used in research on neuroscience, and more recently, in the clinical community. For example, the lateralization of language function assessed by fMRI activation was reported to be consistent with that determined by Wada testing.<sup>4,8</sup> The present study further demonstrated that fMRI can also detect brain activation during Chinese word processing. Many of the language related structures, including Broca's area, Wernicke's area, SMA, extrastriate visual areas and ventral temporal cortex were activated in our experiments. Thus, in addition to the reliable determination of the lateralization of language function, fMRI allows for more precise localization of functional areas in the living human brain.

Traditional neuropsychological studies in brain damaged patients and more recent neural image studies in normal volunteers have demonstrated left hemispheric dominance in the processing of alphabetic languages.<sup>9,10</sup> However, several authors proposed a right-hemisphere dominance hypothesis of Chinese word processing based on the prominent pictorial nature of Chinese characters.<sup>11,12</sup> Contrary to this hypothesis, the current study indicated that the brain activity during Chinese word processing was generally in accordance with that of word processing of western languages, with strong left-hemisphere dominance. This is indeed consistent with results from previous studies,<sup>13-15</sup> showing strong left hemispheric activation during listening and reading Chinese words or sentences.

An unexpected finding of the present study was that no significant difference was found in activation areas between semantic and phonological processes. This conflicted with the traditional viewpoint that semantic and phonological processes were two basic operations of word reading.<sup>16</sup> One possible explanation is that both semantic and phonological systems are automatically and spontaneously engaged during word reading whether or not specific instruction is provided. This finding agrees with results achieved by Price et al,<sup>17</sup> who indicated that a mere presence of words activated a widespread activation in the brain even when no explicit linguistic demands were presented. Another explanation is that conflicting results may occur when using different languages. Under the control of the difficulty for employed words, semantic judgment is often more difficult than phonological judgment in western languages (i.e. differences between semantic and phonological judgment is more likely to be detected), while homophones are uncommon in western languages. In Chinese, however, the differences between semantic and phonological judgments are relatively small, and both synonyms and homophones are more common, resulting in the finding of no significant

differences between Chinese synonym and homophone judgments in our test.

To examine the reproducibility and the reliability of the study, we respectively conducted the same experiment on 2 different scanners. The data acquired from the 2 scanners can be compared with each other since the same reference wave and correlation coefficient were used in each of the correlation analyses. From the activation maps and time courses in 4 primary activation cortical areas, we revealed almost identical activation in data acquired on different scanners. As a result, the research with fMRI was highly reproducible and reliable.<sup>18</sup>

In the subject who performed the same linguistic tasks on different scanners, however, we did find more activated voxels in the Broca's and Wernicke's areas in the Siemens data set than in the GE data set, but this may be explained as a learning effect. The results of Raichle et al<sup>19</sup> showed that activation in Broca's and Wernicke's areas dramatically decreased when the subjects were reading old, learned English words. In the present study, the subject was asked to read the same Chinese words during 2 experiments performed on different scanners, first on the Siemens scanner, then on the GE scanner.

Because the two MR scanners were located in different countries, the experiment was performed in each of the other 7 subjects only once and the same experiment could not be repeated across the scanners. That is an incomplete aspect of the study and additional experimental programs are under consideration to accomplish the project.

In conclusion, the present study demonstrated that fMRI is feasible for functional localization of Chinese language processing and may become a widely accepted clinical tool for localizing functional brain areas in patients.

#### REFERENCES

1. Wada J, Rasmussen T. Intracarotid injection of sodium amyltal for the lateralization of cerebral speech dominance: experimental and clinical observations. *J Neurosurg* 1960 ;17 266-282.
2. Hollway V, Liegeois F, Baldeweg T, et al. Language lateralization using fMRI in children undergoing Wada testing. *Neuroimage* 2000 ;11 S290.
3. Weng XC, Ding YS, Volkow ND. Imaging the functioning human brain. *Proc Natl Acad Sci U S A* 1999 96 :11073-11074.
4. Desmond JE, Sum JM, Wagner AD, et al. Functional MRI measurement of language lateralization in Wada-tested patients. *Brain* 1995 ;118 :1411-1419.
5. Brockway JP. fMRI may replace the WADA test for language lateralization. *Neuro Image* 2000 ;11 S277.
6. Cox RW. AFNI: software for analysis and visualization of

- functional magnetic resonance neuroimages. *Comput Biomed Res* 1996 29 :162-173.
7. Talairach J , Tournoux P. Co-planar stereotaxic atlas of the human brain. New York : Thieme Medical Publishers ; 1988 :1-120.
  8. Binder JR , Swanson SJ , Hammeke TA , et al. Determination of language dominance using functional MRI : a comparison with the Wada test. *Neurology* 1996 46 :978-984.
  9. Petersen SE , Fiez JA. The processing of single words studied with positron emission tomography. *Ann Rev Neurosci* 1993 ;16 : 509-530.
  10. Fiez JA , Petersen SE. Neuroimaging studies of word reading. *Proc Natl Acad Sci U S A* 1998 95 :914-921.
  11. Hatta T. Recognition of Japanese kanji in the left and right visual fields. *Neuropsychologia* 1977 ;15 :685-688.
  12. Tzeng OJ , Hung DL , Cotton B , et al. Visual lateralization effect in reading Chinese characters. *Nature* 1979 282 :499-501.
  13. Li EZ , Weng XC , Han Y , et al. Asymmetry of brain functional activation : FMRI study under language and music stimulation. *Chin Med J* 2000 ;113 :154-158.
  14. Tan LH , Spinks JA , Gao JH , et al. Brain activation in the processing of Chinese characters and words : a functional MRI study. *Hum Brain Mapp* 2000 ;10 :16-27.
  15. Chee MW , Tan EW , Thiel T. Mandarin and English single word processing studied with functional magnetic resonance imaging. *J Neurosci* 1999 ;19 :3050-3056.
  16. Petersen SE , Fox PT , Posner MI , et al. Position emission tomographic studies of the cortical anatomy of single-word processing. *Nature* 1988 ;331 :585-589.
  17. Price CJ , Wise RJ , Frackowiak RS. Demonstrating the implicit processing of visually presented words and pseudowords. *Cereb Cortex* 1996 6 :62-70.
  18. Tegeler C , Strother SC , Anderson JR , et al. Reproducibility of BOLD-based functional MRI obtained at 4 T. *Hum Brain Mapp* 1999 ;7 :267-283.
  19. Raichle ME , Fiez JA , Videen TO , et al. Practice-related changes in human brain functional anatomy during nonmotor learning. *Cereb Cortex* 1994 ;4 :8-26.

( Received March 5 , 2002 )

本文编辑 : 钱寿初 顾 佳