

# Abnormal grey matter in victims of rape with PTSD in Mainland China: a voxel-based morphometry study

Sui SG, Wu MX, King ME, Zhang Y, Ling L, Xu JM, Weng XC, Duan L, Shan BC, Li LJ. Abnormal grey matter in victims of rape with PTSD in Mainland China: a voxel-based morphometry study.

**Objective:** This study examined changes in brain grey matter in victims of rape (VoR) with and without post-traumatic stress disorder (PTSD).

Previous research has focused on PTSD caused by various traumatic events, such as war and disaster, among others. Although considerable research has focused on rape-related PTSD, limited studies have been carried out in the context of Mainland China.

**Methods:** The study included 11 VoR with PTSD, 8 VoR without PTSD and 12 healthy comparison (HC) subjects. We used voxel-based morphometry to explore changes in brain grey-matter density (GMD) by applying statistical parametric mapping to high-resolution magnetic resonance images.

**Results:** Compared with HC, VoR with PTSD showed significant GMD reductions in the bilateral medial frontal cortex, left middle frontal cortex, middle temporal gyrus and fusiform cortex and significant GMD increases in the right posterior cingulate cortex, postcentral cortex, bilateral precentral cortex and inferior parietal lobule. Compared to VoR without PTSD, VoR with PTSD showed significant GMD reductions in the right uncus, left middle temporal gyrus, and the fusiform cortex, and increases in the left precentral cortex, inferior parietal lobule and right post-central cortex.

**Conclusion:** The findings of abnormal GMD in VoR with PTSD support the hypothesis that PTSD is associated with widespread anatomical changes in the brain. The medial frontal cortex, precentral cortex, posterior cingulate cortex, post-central cortex and inferior parietal lobule may play important roles in the neuropathology of PTSD.

**Shuang Ge Sui<sup>1</sup>, Ming Xiang Wu<sup>2</sup>, Mark E. King<sup>3</sup>, Yan Zhang<sup>1</sup>, Li Ling<sup>3</sup>, Jian Min Xu<sup>2</sup>, Xu Chu Weng<sup>4</sup>, Lian Duan<sup>1</sup>, Bao Ci Shan<sup>5</sup>, Ling Jiang Li<sup>1</sup>**

<sup>1</sup>Mental Health Institute, Second Xiangya Hospital, Central-South University, Changsha, Hunan 410011, P. R. China; <sup>2</sup>Shenzhen People's Hospital, Guangdong 518020, P. R. China; <sup>3</sup>Faculty of Education, The University of Hong Kong, HKSAR, P. R. China; <sup>4</sup>Laboratory for Higher Brain Function, Institute of Psychology, Chinese Academy of Sciences, Beijing 100012, P. R. China; and <sup>5</sup>Institute of High Energy Physics, Chinese Academy of Sciences, Beijing 100049, P. R. China  
Keywords: China; MRI; post-traumatic stress disorder; rape; voxel-based morphometry

Ling Jiang Li, Mental Health Institute, Second Xiangya Hospital, Central-South University, Changsha, Hunan 410011, P. R. China.  
Tel: +86 13807314575;  
Fax: +86 731 85360086;  
E-mail: llij2920@163.com

Bao Ci Shan, Institute of High Energy Physics, Chinese Academy of Sciences, Beijing 100049, P. R. China.  
Tel: +86 13693161965;  
Fax: +86 10 88233186;  
E-mail: shanbc@ihep.ac.cn

## Introduction

Post-traumatic stress disorder (PTSD) is a relatively common and predictable psychological syndrome (1). PTSD occurs in a proportion of individuals exposed to severe psychological trauma (2) and in which the individual responds with fear, helplessness or horror (3). Individuals with PTSD suffer from intrusive memories about the traumatic event, persistent avoidance of stimuli associated with the trauma, and persistent symptoms of increased arousal, symptoms which become uncontrollable and disabling (4).

Because of its debilitating nature, PTSD has emerged as an important public health problem in the general population (5).

In recent years, a great deal of research has been directed towards understanding the etiology, phenomenology, neurobiology, clinical characteristics and treatment of PTSD (6). However, a number of core psychological processes underlying PTSD have yet to be elucidated (7,8). Over the past decade, findings from neuroimaging studies have allowed for tremendous advances in our understanding of

the experience of emotions in healthy individuals and the dysregulation of these processes associated with PTSD. These studies have been useful in both generating hypotheses on the neurobiology of normative human responses to trauma and complementing our understanding of the wide-ranging alterations in trauma survivors who develop PTSD.

Structural neuroimaging studies have focused primarily on hippocampal volumetry (9) as well as the prefrontal cortex (10) and other brain structures. Hippocampal morphology has been correlated with severity of PTSD symptomatology (11,12). However, the results have been inconsistent, with studies reporting significant reductions or increases, as well as unchanged volumes. For example, studies have shown that patients with PTSD are associated with bilateral lower hippocampal volume (13–18), which are considered to be either because of atrophy of the hippocampus as a consequence of suffering from PTSD because of excessive stress (19,20) or that hippocampal volume to be a risk factor for developing PTSD (11). Other studies report unchanged hippocampal volumes in female patients with chronic PTSD traumatised by intimate partner violence (21), those traumatised at the same air show plane crash (22), elderly PTSD patients (23) and adult burn patients (24). One study noted opposite trends in abused juveniles (25). However, a recent meta-analysis confirmed the presence of significantly smaller hippocampal and left amygdala volumes in patients with PTSD compared to controls with and without trauma exposure (26). The findings of previous studies suggest that abnormal hippocampal volume was not a necessary and sufficient condition of PTSD.

Several studies have shown that the medial prefrontal cortex, which includes the anterior cingulate cortex and medial frontal cortex, are involved in the process of extinction of fear conditioning and the retention of extinction (27). Research on abnormalities in the prefrontal cortex in PTSD patients suggest decreased volume (21,28–30), while some findings suggested increased volume of the middle-inferior and ventral regions of the prefrontal cortex (29).

In addition to findings related to the hippocampus and medial prefrontal cortex, many current functional neuroimaging studies have identified other brain areas such as the prefrontal cortex, temporal lobe, parietal lobe, limbic lobe and others that may also be implicated in PTSD (31–36). The findings of functional neuroimaging studies suggest that there are more brain areas that may be affected in PTSD. However, only a few studies have found corresponding structural abnormalities in these brain areas.

In contrast to the considerable research on subcortical structure volumetry, few studies to date

have been directed to grey matter reductions in the cortex. It is evident that structural neuroimaging studies will allow for the testing of hypotheses of an association between PTSD and abnormal grey matter. Although volumetry findings reveal changes in the volume of specific brain regions, most of these studies defined particular regions-of-interests (ROIs) and measured their size and hemispheric asymmetry using traditional morphometric techniques with high-resolution magnetic resonance images (MRI). The disadvantage of this method is that some important brain areas may be neglected, and the process of drawing ROIs may introduce additional error. Furthermore, the measurement of volume may not accurately reflect changes in the internal structure of the brain. In recent years, a fully automated voxel-based morphometry (VBM) technique has allowed for the examination of cerebral asymmetries across the entire brain directly (37–39), which can compensate for the subjectivity of ROI approaches. The VBM technique has been used for assessing regional grey-matter density (GMD) in PTSD patients and revealed abnormal GMD in the hippocampus, anterior cingulate cortex and insula (15,22,29,37,38).

Most previous PTSD studies in the West focused on the disorder caused by various traumatic events, such as war (17,19,40), disaster (22,41–43) and sexual abuse (14,25). Although considerable research has focused on rape-related PTSD, limited studies have been carried out in the context of Mainland China. In this study, rape was defined as an event that occurred without the victim's consent, that involved the use or threat of force to penetrate the victim's vagina or anus by penis, tongue, fingers or object, or the victim's mouth by penis (44). Interestingly, evidence indicates that the incidence rate of PTSD induced by rape is the highest among all kinds of trauma (45).

In the current study, we used VBM to explore differences in GMD between VoR with and without PTSD, as well as in healthy comparison (HC) subjects. Based on findings from previous neuroimaging studies (27–36), we hypothesised that VoR with PTSD would show structural changes in extensive brain areas, including the prefrontal, temporal, parietal and limbic regions, compared to VoR without PTSD and to HC.

### Material and methods

#### Subjects

We conducted a cross-sectional study on VoR and HC in Guangdong Province, People's Republic of China. Subjects living and working in Guangdong who met the following criteria were included: females, at least 18 years old, right-handed, with an educational

attainment above secondary school level. Exclusion criteria for VoR and HC were a history of neurological or brain trauma and alcohol or drug use/abuse. Additional exclusion criteria for VoR included a previous or current psychiatric diagnosis other than PTSD, and for HC included any previous or current Diagnostic and Statistical Manual of Mental Disorders-Fourth Edition (DSM-IV) psychiatric disorder. The Ethics Committee of the Second Xiangya Hospital, Central South University, the People's Republic of China approved the study protocol. Written informed consent was obtained from all subjects in the study. The sample size for this study was projected based on previous research (16,21,22,41) where sample sizes ranging from 8 to 20 were reported.

*VoR subjects.* VoR subjects were recruited in two stages. In the first stage, 53 potential subjects were recruited from (a) four public psychological consulting clinics, (b) referred to the clinics by a non-government organisation specialising in assisting victims of sexual assault and (c) through advertisements in local newspapers requesting VoR for brain imaging studies. As an incentive for participation, 6 months free psychological counseling and medical therapy were offered. In the second stage, psychiatrists in the four consulting clinics explained the study to the 53 potential subjects and requested consent to participate in this study. As a result, 23 VoR met the inclusion/exclusion criteria and gave written informed consent.

*HC subjects.* The HC subjects for this study were also recruited through a two-stage process. First, after obtaining the major demographic characteristics (i.e. gender, race, age, height, weight and educational years) of VoR, we published notices across the province to recruit female health workers with similar demographic characteristics. A total of 65 volunteers agreed to participate and were screened according to inclusion/exclusion criteria. The health status of the HC was determined based on health check reports, as well as an illness history interview conducted by a doctor and a psychiatrist. In the second stage, the exact number of HC was recruited to best match the major demographic characteristics of each case of VoR with PTSD.

In this study, all subjects were measured with the Trauma History Questionnaire (46) and the PTSD Checklist Civilian Version (PCL-C) (47). In addition, two independent, clinically experienced psychiatrists interviewed VoR subjects using the Clinician-Administered PTSD Scale (CAPS) (48). The PCL-C was used to predict PTSD diagnoses, and the CAPS was used to differentiate PTSD and non-PTSD VoR

subgroups. A senior psychiatrist confirmed the final diagnosis of PTSD.

#### MRI data acquisition

Images were obtained from using a research-dedicated Siemens Avanto 1.5 T MRI scanner. The T1-weighted anatomical images were acquired using a three-dimensional gradient-echo sequence, with time of repetition (TR) = 11 ms, echo time (TE) = 4.94 ms, number of averages = 1, matrix = 256 × 224 pixels, field of view = 256 × 224 mm, with a flip angle of 15°. One-hundred and seventy-six sagittal slices with a 1-mm slice thickness were acquired with no interslice gap. There was a voxel resolution of 1 × 1 × 1 mm<sup>3</sup>. The total acquisition time was 5 min and 34 s.

#### MRI data analysis

VBM were implemented by using the Statistical Parametric Mapping software (SPM2) (Wellcome Department of Imaging Neuroscience, London, England; www.fil.ion.ucl.ac.uk) (49). Images were firstly spatially normalised to the Montreal Neurological Institute (MNI) space with the standard T<sub>1</sub>-MRI template (50) implemented in the SPM2 program, and re-sliced into a final voxel size of 1 × 1 × 1 mm<sup>3</sup> using tri-linear interpolation. The spatially normalised images were then segmented into three compartments: grey matter, white matter and cerebrospinal fluid, respectively. Finally, the segmented grey matter images from VoR with PTSD, VoR without PTSD and HC were smoothed with a 12-mm full-width at half-maximum isotropic Gaussian kernel (51). Between-group comparisons of grey matter images were performed in the general linear model.

Because we are particularly interested in exploring increases/decreases in GMD in VoR with PTSD compared to VoR without PTSD and HC, two-sample *t*-tests were performed in the VBM analysis in a voxel-by-voxel manner. Consistent with previous studies (52,53), the significance threshold was set to  $p < 0.005$  corrected for multiple comparisons with a minimal cluster size of >50 voxels. The significant regions were superimposed onto SPM2's standard T<sub>1</sub>-weighted brain images.

Based on previous research (27–36), we hypothesised that compared with HC, VoR with PTSD would show grey matter abnormalities in the prefrontal, temporal, parietal and limbic regions. We used the small volume correction tool in the SPM2 package with the specific purpose of restricting comparisons to specific voxels located in these regions. This approach permits the implementation of hypothesis-driven analyses with corrections for

the pre-specified ROIs rather than corrections for the whole brain.

**Results**

Following the initial interview, among the 23 VoR subjects, 13 met the DSM-IV diagnostic criteria for current PTSD and 10 VoR did not meet the criteria for PTSD. Based on the study protocol, 13 HC were recruited to match VoR with PTSD. All subjects were scanned with MRI. However, because of too many head movements during MRI scanning, a total of five subjects (2 PTSD, 2 non-PTSD and 1 HC) were removed. As a result, the final sample consisted of 11 VoR with PTSD (18–31 years), 8 VoR without PTSD (23–33 years) and 12 HC (22–33 years).

The three groups did not differ significantly on major demographics (i.e. age, height, weight and educational years). In addition, the average interval between rape trauma and data acquisition did not differ significantly between VoR with and without PTSD. However, VoR with PTSD scored significantly higher on PTSD symptomatology ( $p < 0.001$ ) compared to VoR without PTSD and HC. None of the participants in this study received medication prior to neuroimaging acquisition. The results are summarised in Table 1.

Table 1. Demographic and clinical characteristics of VoR with and without PTSD and healthy comparison

	VoR ( $n = 19$ )		Healthy comparison ( $n = 12$ )	$F$	$t$	$p$
	PTSD ( $n = 11$ )	Non-PTSD ( $n = 8$ )				
Age (years)						
Mean	25.55	27.50	26.42	0.614	–	0.55
SD	4.01	4.00	3.45			
Education (years)						
Mean	14.73	15.63	14.83	0.91	–	0.41
SD	1.62	1.92	1.12			
Hight (CM)						
Mean	157.82	159.25	160.67	0.83	–	0.45
SD	5.44	5.81	4.77			
Weight (KG)						
Mean	49.00	51.13	50.88	0.41	–	0.67
SD	4.13	6.19	6.81			
Trauma event	Raped	Raped	None	–	–	–
Interval (months)						
Mean	45.45	53.50	–	–	–.31	0.76
SD	55.68	55.54	–			
PCL-C score						
Mean	60.36	34.63	22.58	60.32	–	0.000
SD	8.39	8.96	7.89			
CAPS score						
Mean	74.45	15.88	–	–	14.70	0.000
SD	8.30	8.95	–			

CM, centimeter; KG, kilogram; Interval, time between raped trauma occurrence and scan; SD, standard deviation.

Differences in GMD between VoR with PTSD and HC

The areas found to have abnormal GMD in VoR with PTSD compared to HC are shown in Fig. 1. The cortical areas with decreased GMD in VoR with PTSD compared to HC are listed in Part a of Fig. 1. These areas include the left medial frontal cortex (Fig. 1a-1), right medial frontal cortex (Fig. 1a-2), the left middle frontal cortex (Fig. 1a-3), the left middle temporal gyrus (Fig. 1a-4) and the left fusiform cortex (Fig. 1a-5). The areas with increased GMD are listed in Part b of Fig. 1, and include the right posterior cingulate cortex (Fig. 1b-1), the left precentral cortex (Fig. 1b-2), right precentral cortex (Fig. 1b-3), the left inferior parietal lobule (Fig. 1b-4), right inferior parietal lobule (Fig. 1b-5) and the right postcentral cortex (Fig. 1b-6). The MNI coordinates, voxel  $t$  values,  $k$  values (cluster size  $>50$ ), and corresponding Brodmann Areas (BA) are detailed in Table 2. Regions displayed are for  $p < 0.005$ .

Differences in GMD between VoR with and without PTSD

The areas found to have abnormal GMD in VoR with PTSD compared to the VoR without PTSD are shown in Fig. 1. The cortical areas with decreased GMD are listed in Part c of Fig. 1. These areas include the right uncus (Fig. 1c-1), the left middle temporal gyrus (Fig. 1c-2), and the left fusiform cortex (Fig. 1c-3). The areas with increased GMD are listed in Part d of Fig. 1, and include the left precentral cortex (Fig. 1d-1), the left inferior parietal lobule (Fig. 1d-2), and the right postcentral cortex (Fig. 1d-3). The MNI coordinates, voxel  $t$  values,  $k$  values (cluster size  $>50$ ), and corresponding BA are detailed in Table 3. Regions displayed are for  $p < 0.005$ .

Table 2. GMD in victims of rape with PTSD vs. healthy comparison

$k$	Voxel $t$ value	MNI coordinates ( $x, y, z$ )	Region	Brodmann area	$p$
143	3.85	–9, 68, 11	Left medial frontal cortex	10	0.001
318	3.73	4, 64, –4	Right medial frontal cortex	10	0.001
398	4.67	–31, 54, 2	Left middle frontal cortex	10	0.000
51	3.11	–51, 7, –26	Left middle temporal gyrus	21	0.003
718	4.75	–31, –82, –18	Left fusiform cortex	19, 20	0.000
Greater increase					
449	3.57	4, –64, 7	Right posterior cingulate	30, 23	0.001
240	3.02	–41, –16, 55	Left precentral cortex	4	0.003
343	3.77	42, –18, 62	Right precentral cortex	4, 6	0.001
64	3.34	–53, –34, 21	Left inferior parietal lobule	40	0.002
211	3.77	57, –27, 33	Right inferior parietal lobule	40	0.001
412	4.17	55, –28, 35	Right postcentral cortex	2, 3	0.000

$k$ , cluster size.

Regions displayed are for  $p < 0.005$ ,  $k > 50$ .



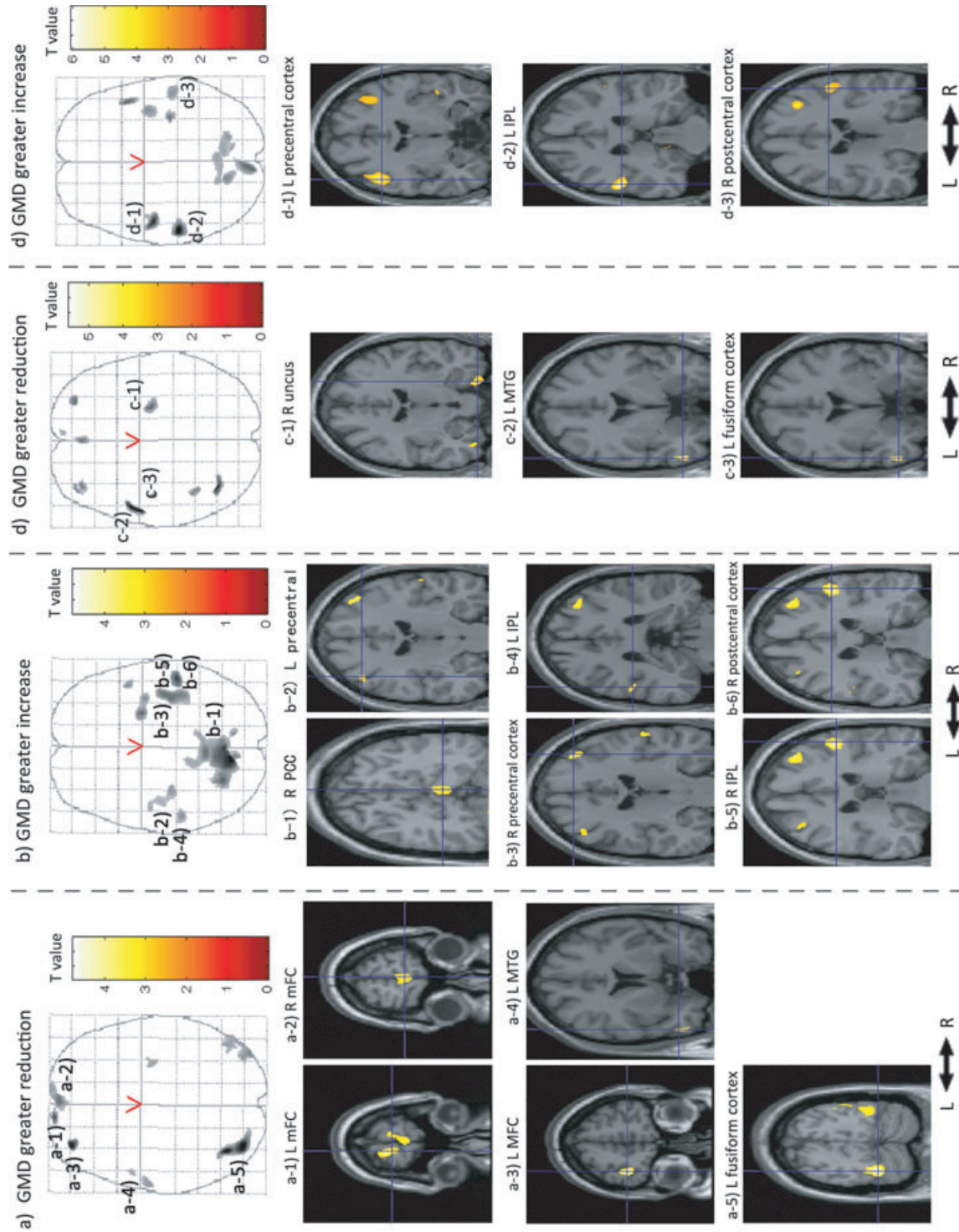


Fig. 1. Part (a) shows the cortical areas with decreased GMD in VoR with post-traumatic stress disorder compared to HC. Part (b) shows the areas with increased GMD. Part (c) shows the cortical areas with decreased GMD in VoR with PTSD compared to VoR without PTSD. Part (d) shows the areas with increased GMD. IPL, inferior parietal lobule; L, left; MFC, middle frontal cortex; mFC, medial frontal cortex; MTG, middle temporal gyrus; PCC, posterior cingulate cortex; R, right.

Table 3. GMD in VoR with PTSD vs. VoR without PTSD

k	Voxel t value	MNI coordinates		Region	Brodmann area	p
		(x, y, z)				
Greater reduction						
173	4.23	27, -10, -35		Right uncus	20, 28	0.000
314	5.56	-55, -1, -26		Left middle temporal gyrus	21	0.000
53	5.23	-54, -1, -27		Left fusiform cortex	20	0.000
Greater increase						
993	5.31	-48, -8, 39		Left precentral cortex	6, 4	0.000
607	6.03	-55, -29, 21		Left inferior parietal lobule	40	0.001
270	3.79	54, -23, 33		Right postcentral cortex	2	0.000

k, cluster size.

Regions displayed are for  $p < 0.005$ ,  $k > 50$ .

**Discussion**

This cross-sectional study used VBM to examine GMD abnormalities among VoR with PTSD compared to VoR without PTSD and HC in mainland China. The findings of this study support the hypothesis that changes in GMD are associated with the pathophysiology of rape-induced PTSD.

The frontal cortex

The structural abnormalities in the medial and middle frontal cortex found in VoR with PTSD are supported by previous studies (7,21,29,30). In addition to such structural findings, functional neuroimaging studies have also shown dysfunction in these cortical areas (14,54–59). It is therefore possible that altered GMD in the medial and middle frontal cortex may contribute to their hypofunction. However, in the current study, VoR with PTSD had GMD reductions in the left middle frontal cortex and the bilateral medial frontal cortex relative to the HC, but no significant differences relative to VoR without PTSD. This result suggests that severe psychological trauma may change brain grey matter of the medial and middle frontal cortex, but that such plastic changes to these cortical brain structures may not underlie the pathophysiology of PTSD.

Compared to VoR without PTSD and HC, VoR with PTSD had significant bilateral increases in GMD of the precentral gyrus, which mainly consists of the premotor cortex and the supplementary motor area. Studies indicate the importance of the supplementary motor area in motor tasks that demand retrieval of motor memory (60). The premotor cortex, located in the precentral cortex (BA6), seems to play a major role in language (61). Functional neuroimaging studies on PTSD suggest abnormal functional activities in this cortical area. Empirical studies have shown that PTSD groups are characterised by relatively more activation in the precentral

cortex than non-PTSD and HCs (31,54,55,62,63). These findings suggest that increases in GMD of the precentral cortex may be involved in the neural basis of motor and linguistic PTSD symptomatology.

The parietal lobule

The parietal lobule, including the superior and inferior parietal lobule (BA7, BA40) is implicated in memory, recognition, and deductive reasoning (64,65). In this study, compared to VoR without PTSD and HC, VoR with PTSD had significant increases in GMD of the inferior parietal lobule. This indicates that the inferior parietal lobule might play an important role in the pathophysiology of PTSD. In addition, one positron emission tomography (PET) study showed that chronic PTSD patients presented relatively diminished activity in the post-central regions (33), which mainly consist of the primary somatic sensory cortex and secondary somatic sensory cortex (66). Increases in GMD in the post-central cortex may be associated with the dysfunction associated with PTSD.

The temporal gyrus

Our study showed significant GMD decreases in the left middle temporal gyrus in VoR with PTSD compared to HC. Studies comparing veterans with and without PTSD revealed that those with PTSD had overactivation of the temporal gyrus during the resting state (33) and the encoding phase (67) and underactivation of the bilateral middle temporal gyrus in the retrieval phase (67). Functional neuroimaging studies revealed significant activation in left middle temporal gyrus in response to empathy judgments in post-therapy PTSD (68) and higher levels of activation in the middle temporal gyrus in dissociative PTSD (55). Empirical evidence suggests that the fusiform cortex is specialised for face processing (69,70). Research also indicates relatively augmented activity in the fusiform cortex in patients with PTSD (31,33). The reduced GMD of the middle temporal gyrus and fusiform cortex found in this study implicates these regions in the dysfunction of memory and dissociative symptoms in PTSD.

The limbic lobe

In the present study, VoR with PTSD had significant increases in GMD in the right posterior cingulate cortex compared to HC. Meta-analyses have revealed that the prominent themes in the posterior cingulate cortex are episodic memory retrieval and pain (71), visuospatial processing and assessment of threat (6), as well as fear conditioning (72). Comparison of connectivity maps by functional connectivity analyses

(56) revealed that subjects with PTSD showed greater correlations in interregional brain activity than subjects without PTSD in the right posterior cingulate cortex (BA 29). Functional neuroimaging studies have found increased activation in the posterior cingulate cortex in victims with PTSD compared to victims without PTSD and to healthy controls (14,54,72–74). This indicates that dysfunction in the posterior cingulate cortex may underlie pathological symptoms provoked by traumatic reminders of sexual assault among VoR with PTSD.

It should be noted that whilst the sample size (11 VoR with PTSD) of this study meets the threshold of research reported in the literature (22,53), it was nevertheless limited in terms of its statistical power. A further limitation is the potential for selection bias in both the VoR Group and HC. Given the social stigma attached to VoR in the Chinese cultural context that often results in sexual shame, fear and anxiety over disclosure of the rape, guilt over derogating family honor, self-scrutiny and self-blame after the fact, and even blame of the victim, contribute to the potential selection bias in the VoR Group. Regarding the selection bias in HC, it was not our intention for this group (12 HC) to be representative of the general population, nor were the 65-pooled controls. This group was particularly designed to match the VoR with PTSD regarding the major demographic characteristics. However, given the fact that HC were recruited from healthy workers, selection bias from the healthy-worker effect should be borne in mind.

The use of a cross-sectional design is another significant limitation of this study. The shared variance estimated between variables in a cross-sectional design does not allow for a critical examination of causal relationships among them. Consequently, we cannot state categorically whether changes in GMD were the cause or the effect of trauma exposure/PTSD. Future studies using case-control or longitudinal designs need to be conducted to explore experiences of rape and associated PTSD symptomatology. In addition, the impact of the specific social and cultural meanings of rape and the impact on the individual's post-traumatic response and ability to cope should also be investigated.

## Conclusion

The abnormal GMD of cerebral regions in VoR with PTSD supports the hypothesis that PTSD is associated with structural plastic changes to brain grey matter. The results suggest that the medial frontal cortex, precentral cortex, posterior cingulate cortex, postcentral cortex and inferior parietal lobule are likely to contribute to the neural mechanisms underlying PTSD.

## Acknowledgements

We acknowledge support from grant from the National Natural Science Foundation of China (30830046 to Lingjiang Li and Shuangge Sui), the National Science and Technology Program of China (2007 BAI17B02 to Lingjiang Li and Shuangge Sui), the National 973 Program of China (2009CB918303, 2006CB5000800 to Lingjiang Li); Program of Chinese Ministry of Education (20090162110011 to Lingjiang Li).

## References

- MILLER L. Atypical psychological responses to traumatic brain injury: PTSD and beyond. *Neurorehabilitation* 1999; **13**:79–90.
- KASAI K, YAMASUE H, ARAKI T, SAKAMOTO H, KATO N. Structural and functional neuroimaging in posttraumatic stress disorder. In: PTSD: brain mechanisms and clinical implications. Japan: Springer, 2006, pp 203–209.
- DANCKWERTS A, LEATHEM J. Questioning the link between PTSD and cognitive dysfunction. *Neuropsychol Rev* 2003; **13**:221–235.
- BREMNER JD, CHARNEY DS. Neurobiology of posttraumatic stress disorder – implications for treatment. *Int Acad Biomed Drug Res* 1994; **8**:171–186.
- SAREEN J, COX BJ, STEIN MB, AFIFI TO, FLEET C, ASMUNDSON GJG. Physical and mental comorbidity, disability, and suicidal behavior associated with posttraumatic stress disorder in a large community sample. *Psychosom Med* 2007;**69**:242–248.
- NEMEROFF CB, BREMNER JD, FOA EB, MAYBERG HS, NORTH CS, STEIN MB. Posttraumatic stress disorder: A state-of-the-science review. *J Psychiatr Res* 2006;**40**:1–21.
- SHIN LM, RAUCH SL, PITMAN RK. Amygdala, medial prefrontal cortex, and hippocampal function in PTSD. *Ann N Y Acad Sci* 2006;**1071**:67–79.
- LIBERZON I, SRIPADA CS. The functional neuroanatomy of PTSD: a critical review. *Stress hormones and post traumatic stress disorder: basic studies and clinical perspectives* 2008;**167**:151–169.
- GEUZE E, VERMETTEN E, BREMNER JD. MR-based in vivo hippocampal volumetrics: 2. Findings in neuropsychiatric disorders. *Mol Psychiatry* 2005;**10**:160–184.
- GEUZE E, VERMETTEN E, GOEBEL R, WESTENBERG H. Thinner prefrontal cortex in veterans with posttraumatic stress disorder. *Biol Psychiatry* 2008;**63**:174S–174S.
- GILBERTSON M, SHENTON M, CISZEWSKI A et al. Smaller hippocampal volume predicts pathologic vulnerability to psychological trauma. *Nat Neurosci* 2002;**5**:1242–1247.
- VILLARREAL G, KING CY. Neuroimaging studies reveal brain change in posttraumatic stress disorder. *Psychiatr Ann* 2004;**34**:845–856.
- BOSSINI L, CASTROGIOVANNI P. Pre- and posttreatment neuroimaging of PTSD: focus on hippocampal volume. *J Psychosom Res* 2007;**63**:310.
- BREMNER JD, VYTHILINGAM M, VERMETTEN E et al. Neural correlates of declarative memory for emotionally valenced words in women with posttraumatic stress disorder related to early childhood sexual abuse. *Biol Psychiatry* 2003;**53**:879–889.



15. EMDAD R, BONEKAMP D, SONDERGAARD HP et al. Morphometric and psychometric comparisons between non-substance-abusing patients with posttraumatic stress disorder and normal controls. *Psychother Psychosom* 2006;**75**:122–132.
16. LINDAUER RJL, VLIENER EJ, JALINK M et al. Smaller hippocampal volume in dutch police officers with posttraumatic stress disorder. *Biol Psychiatry* 2004;**56**:356–363.
17. VYTHILINGAM M, LUCKENBAUGH DA, LAM T et al. Smaller head of the hippocampus in Gulf War-related post-traumatic stress disorder. *Psychiatry Res Neuroimaging* 2005;**139**:89–99.
18. LI LJ, CHEN SL, LI J, ZHANG JL, HE Z, LIN X. Magnetic resonance imaging and magnetic resonance spectroscopy study of deficits in hippocampal structure in fire victims with recent-onset posttraumatic stress disorder. *Can J Psychiatry* 2006;**51**:431–437.
19. BREMNER JD, RANDALL P, SCOTT TM et al. MRI-based measurement of hippocampal volume in patients with combat-related posttraumatic-stress-disorder. *Am J Psychiatry* 1995;**152**:973–981.
20. GURVITS TV, SHENTON ME, HOKAMA H et al. Magnetic resonance imaging study of hippocampal volume in chronic, combat-related posttraumatic stress disorder. *Biol Psychiatry* 1996;**40**:1091–1099.
21. FENNEMA-NOTESTINE C, STEIN MB, KENNEDY CM, ARCHIBALD SL, JERNIGAN TL. Brain morphometry in female victims of intimate partner violence with and without posttraumatic stress disorder. *Biol Psychiatry* 2002;**52**:1089–1101.
22. JATZKO A, ROTHENHOFER S, SCHMITT A et al. Hippocampal volume in chronic posttraumatic stress disorder (PTSD): MRI study using two different evaluation methods. *J Affect Disord* 2006;**94**:121–126.
23. GOLIER JA, HARVEY PD, LEGGE J, YEHUDA R. Memory performance in older trauma survivors – implications for the longitudinal course of PTSD, vol. 1071, *Psychobiology of posttraumatic stress disorder: a decade of progress* 2006: 54–66.
24. WINTER H, IRLE E. Hippocampal volume in adult burn patients with and without posttraumatic stress disorder. *Am J Psychiatry* 2004;**161**:2194–2200.
25. TUPLER LA, DE BELLIS MD. Segmented hippocampal volume in children and adolescents with posttraumatic stress disorder. *Biol Psychiatry* 2006;**59**:523–529.
26. KARL A, SCHAEFER M, MALTA LS, DORFEL D, ROHL-EDER N, WERNER A. A meta-analysis of structural brain abnormalities in PTSD. *Neurosci Biobehav Rev* 2006;**30**:1004–1031.
27. MILAD MR, RAUCH SL, PITMAN RK, QUIRK GJ. Fear extinction in rats: implications for human brain imaging and anxiety disorders. *Biol Psychology* 2006;**73**:61–71.
28. CARRION VG, WEEMS CF, ELIEZ S et al. Attenuation of frontal asymmetry in pediatric posttraumatic stress disorder. *Biol Psychiatry* 2001;**50**:943–951.
29. RICHERT KA, CARRION VG, KARCHEMSKIY A, REISS AL. Regional differences of the prefrontal cortex in pediatric PTSD: an MRI study. *Depress Anxiety* 2006;**23**:17–25.
30. HAKAMATA Y, MATSUOKA Y, INAGAKI M et al. Structure of orbitofrontal cortex and its longitudinal course in cancer-related post-traumatic stress disorder. *Neurosci Res* 2007;**59**:383–389.
31. BONNE O, GILBOA A, LOUZOUN Y et al. Resting regional cerebral perfusion in recent posttraumatic stress disorder. *Biol Psychiatry* 2003;**54**:1077–1086.
32. LANIUS RA, WILLIAMSON PC, BLUHM RL et al. Functional connectivity of dissociative responses in posttraumatic stress disorder: a functional magnetic resonance imaging investigation. *Biol Psychiatry* 2005;**57**:873–884.
33. MOLINA ME, ISOARDI R, PRADO MN, BENTOLILA S. Basal cerebral glucose distribution in long-term post-traumatic stress disorder. *World J Biol Psychiatry* 2007;**13**:1–9.
34. BREMNER JD. Traumatic stress: effects on the brain. *Dialogues Clin Neurosci* 2006;**8**:445–461.
35. BREMNER JD, ELZINGA B, SCHMAHL C, VERMETTEN E. Structural and functional plasticity of the human brain in posttraumatic stress disorder, vol. 167, *Stress hormones and post traumatic stress disorder: basic studies and clinical perspectives*. 2008: 171–186.
36. GEUZE E, WESTENBERG HGM, HEINECKE A, DE KLOET CS, GOEBEL R, VERMETTEN E. Thinner prefrontal cortex in veterans with posttraumatic stress disorder. *Neuroimage* 2008;**41**:675–681.
37. CORBO V, CLEMENT MH, ARMONY JL, PRUESSNER JC, BRUNET A. Size versus shape differences: contrasting voxel-based and volumetric analyses of the anterior cingulate cortex in individuals with acute posttraumatic stress disorder. *Biol Psychiatry* 2005;**58**:119–124.
38. KASAI K, YAMASUE H, GILBERTSON MW, SHENTON ME, RAUCH SL, PITMAN RK. Evidence for acquired pregenual anterior cingulate gray matter loss from a twin study of combat-related posttraumatic stress disorder. *Biol Psychiatry* 2008;**63**:550–556.
39. LUDERS E, GASER C, JANCKE L, SCHLAUG G. A voxel-based approach to gray matter asymmetries. *Neuroimage* 2004;**22**:656–664.
40. PAVIC L, GREGUREK R, RADOS M et al. Smaller right hippocampus in war veterans with posttraumatic stress disorder. *Psychiatry Res Neuroimaging* 2007;**154**:191–198.
41. ABE O, YAMASUE H, KASAI K et al. Voxel-based diffusion tensor analysis reveals aberrant anterior cingulum integrity in posttraumatic stress disorder due to terrorism. *Psychiatry Res Neuroimaging* 2006;**146**:231–242.
42. LI LJ, CHEN SL, LIU J, ZHANG JL, HE Z, LIN X. Magnetic resonance imaging a magnetic resonance spectroscopy study of deficits in hippocampal structure in fire victims with recent-onset posttraumatic stress disorder. *Can J Psychiatry* 2006;**51**:431–437.
43. YAMASUE H, KASAI K, IWANAMI A et al. Voxel-based analysis of MRI reveals anterior cingulate gray-matter volume reduction in posttraumatic stress disorder due to terrorism. *Proc Natl Acad Sci U S A* 2003;**100**:9039–9043.
44. TJADEN P, THOENNES N. Full report of the prevalence, incidence, and consequences of violence against women. Washington, National Institute of Justice, 2000.
45. ROTHBAUM BO, FOA EB, RIGGS DS, MURDOCK T, WALSH W. A prospective examination of posttraumatic-stress-disorder in rape victims. *J Trauma Stress* 1992;**5**:455–475.
46. GREEN BL. Trauma history questionnaire. In: STAMM BH ed. *Measurement of stress, trauma, and adaptation* Lutherville: Sidran Press, 1996, pp 366–369.
47. RUGGIERO KJ, BEN KD, SCOTTI JR, RABALAI AE. Psychometric properties of the PTSD checklist – civilian version. *J Trauma Stress* 2003;**16**:495–502.



48. BLAKE DD, WEATHERS FW, NAGY LM et al. The development of a clinician-administered PTSD scale. *J Trauma Stress* 1995;**8**:75–90.
49. FRISTON KJ, HOLMES AP, WORSLEY KJ, POLINE JB, FRITH CD, FRACKOWIAK RSJ. Statistical parametric maps in functional imaging: a general linear approach. *Hum Brain Mapp* 1995;**2**:189–210.
50. MAZZIOTTA JC, TOGA AW, EVANS A, FOX P, LANCASTER J. A probabilistic atlas of the human brain: theory and rationale for its development. The International Consortium for Brain Mapping (ICBM). *Neuroimage* 1995;**2**: 89–101.
51. ASHBURNER J, FRISTON KJ. Voxel-based morphometry – the methods. *Neuroimage* 2000;**11**:805–821.
52. LIBERZON I, KING AP, BRITTON JC, PHAN KL, ABELSON JL, TAYLOR SF. Paralimbic and medial prefrontal cortical involvement in neuroendocrine responses to traumatic stimuli. *Am J Psychiatry* 2007;**164**:1250–1258.
53. HOU CL, LIU J, WANG K et al. Brain responses to symptom provocation and trauma-related short-term memory recall in coal mining accident survivors with acute severe PTSD. *Brain Res* 2007;**1144**:165–174.
54. BREMNER JD, STAIB LH, KALOUPEK D, SOUTHWICK SM, SOUFER R, CHARNEY DS. Neural correlates of exposure to traumatic pictures and sound in Vietnam combat veterans with and without posttraumatic stress disorder: a positron emission tomography study. *Biol Psychiatry* 1999;**45**:806–816.
55. LANIUS RA, BLUHM R, LANIUS U, PAIN C. A review of neuroimaging studies in PTSD: heterogeneity of response to symptom provocation. *J Psychiatr Res* 2006;**40**:709–729.
56. LANIUS RA, WILLIAMSON PC, DENSMORE M et al. The nature of traumatic memories: a 4-T fMRI functional connectivity analysis. *Am J Psychiatry* 2004;**161**:36–44.
57. LINDAUER RJL, BOOIJ J, HABRAKEN JBA et al. Cerebral blood flow changes during script-driven imagery in police officers with posttraumatic stress disorder. *Biol Psychiatry* 2004;**56**:853–861.
58. LINDAUER RJL, BOOIJ J, HABRAKEN JBA et al. Effects of psychotherapy on regional cerebral blood flow during trauma imagery in patients with post-traumatic stress disorder: a randomized clinical trial. *Psychol Med* 2008;**38**:543–554.
59. MOREY RA, PETTY CM, COOPER DA, LABAR KS, MCCARTHY G. Neural systems for executive and emotional processing are modulated by symptoms of posttraumatic stress disorder in Iraq War veterans. *Psychiatry Res Neuroimaging* 2008;**162**:59–72.
60. TANJI J. The supplementary motor area in the cerebral-cortex. *Neurosci Res* 1994;**19**:251–268.
61. DUFFAU H, CAPELLE L, DENVIL D et al. The role of dominant premotor cortex in language: a study using intraoperative functional mapping in awake patients. *Neuroimage* 2003;**20**:1903–1914.
62. SHAW ME, STROTHER SC, MCFARLANE AC et al. Abnormal functional connectivity in posttraumatic stress disorder. *Neuroimage* 2002;**15**:661–674.
63. JATZKO A, SCHMITT A, DEMIRAKCA T, WEIMER E, BRAUS D. Disturbance in the neural circuitry underlying positive emotional processing in post-traumatic stress disorder (PTSD) – an fMRI study. *Eur Arch Psychiatry Clin Neurosci* 2006;**256**:112–114.
64. XIE S, XIAO JX, BAI J, JIANG XX. Memory tasks in normal aged volunteers: an fMRI study. *China J Med Imaging Technol* 2004;**20**:571–574.
65. KNAUFF M, MULACK T, KASSUBEK J, SALIH HR, GREENLEE MW. Spatial imagery in deductive reasoning: a functional MRI study. *Cogn Brain Res* 2002;**13**:203–212.
66. GENG JJ, EGER E, RUFF CC, KRISTJANSSON A, ROTSHTEIN P, DRIVER J. On-line attentional selection from competing stimuli in opposite visual fields: effects on human visual cortex and control processes. *J Neurophysiol* 2006;**96**:2601–2612.
67. GEUZE E, VERMETTEN E, RUF M, DE KLOET CS, WESTENBERG HGM. Neural correlates of associative learning and memory in veterans with posttraumatic stress disorder. *J Psychiatr Res* 2008;**42**:659–669.
68. FARROW TFD, HUNTER MD, WILKINSON ID et al. Quantifiable change in functional brain response to empathic and forgiveness judgments with resolution of post-traumatic stress disorder. *Psychiatry Res: Neuroimaging* 2005;**140**:45–53.
69. ROSSION B, DRICOT L, DEVOLDER A et al. Hemispheric asymmetries for whole-based and part-based face processing in the human fusiform gyrus. *J Cogn Neurosci* 2000;**12**:793–802.
70. RHODES G, BYATT G, MICHIE PT, PUCE A. Is the fusiform face area specialized for faces, individuation, or expert individuation? *J Cogn Neurosci* 2004;**16**:189–203.
71. NIELSEN FA, BALSLEV D, HANSEN LK. Mining the posterior cingulate: segregation between memory and pain components. *Neuroimage* 2005;**27**:520–532.
72. DORONBEKOV TK, TOKUNAGA H, IKEJIRI Y et al. Neural basis of fear conditioning induced by video clip: positron emission tomography study. *Psychiatry Clin Neurosci* 2005;**59**:155–162.
73. SACHINVALA N, KLING A, SUFFIN S, LAKE R, COHEN M. Increased regional cerebral perfusion by Tc-99m hexamethyl propylene amine oxime single photon emission computed tomography in post-traumatic stress disorder. *Mil Med* 2000;**165**:473–479.
74. BREMNER JD, NARAYAN M, STAIB LH, SOUTHWICK SM, MCGLASHAN T, CHARNEY DS. Neural correlates of memories of childhood sexual abuse in women with and without posttraumatic stress disorder. *Am J Psychiatry* 1999;**156**:1787–1795.